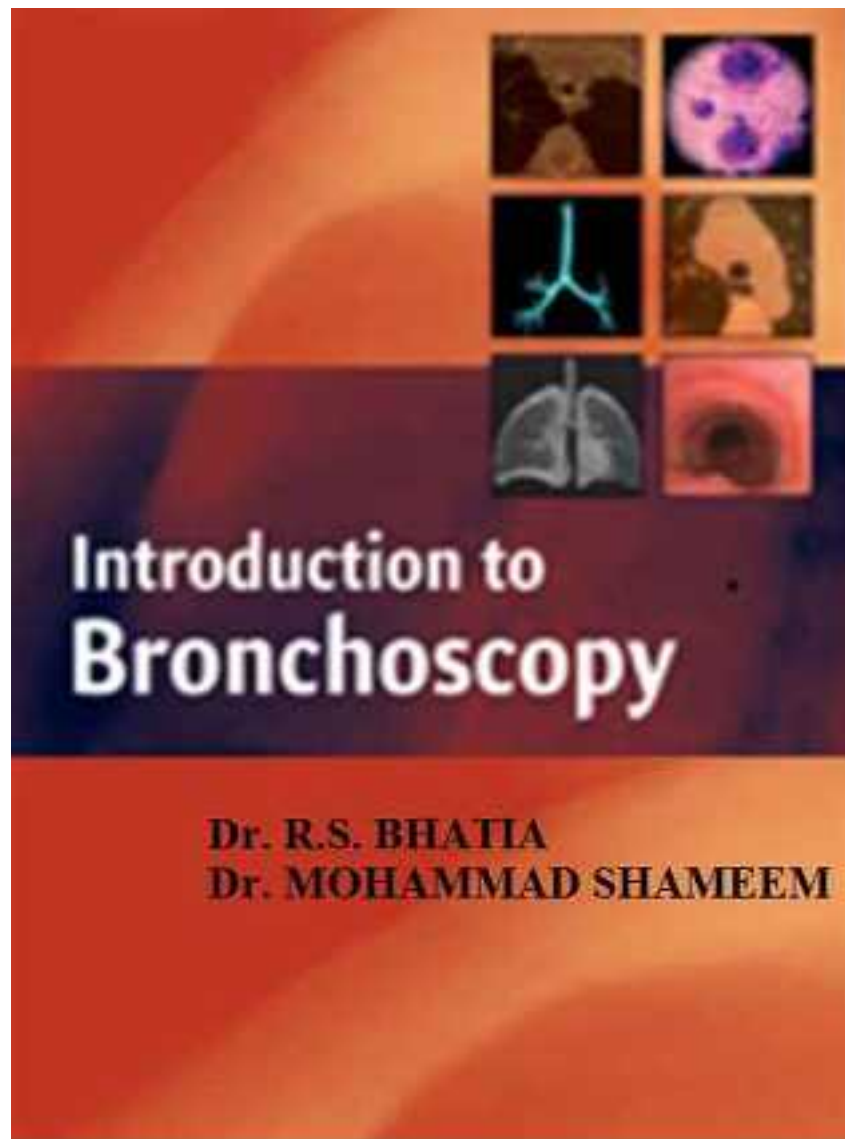

**AN INTRODUCTION TO BRONCHOSCOPY**

First Edition

**Dr. R.S. BHATIA,**

Consult, Chest Physician, Model Town, Ludhiana, India.

**Dr. Mohammad Shameem**

Associate Professor, Department of Pulmonary Medicine,  
Jawaharlal Nehru Medical College, Aligarh Muslim University,  
Aligarh, UP, India.

© All Right Reserved

*Publishers:*

**Nairjc Publications**

221, Pulwama, Jammu & Kashmir, India.

Ph.: 01933-212815, 7298754556

E-mail: *info@nairjc.com*

Website: *www.nairjc.com*

ISBN: 13-978-81-93260X-X-X

**First Edition:** 2016

Price: 275

Printers:

Nairjc Offset

Pulwama, Jammu & Kashmir-192301

**ABOUT THE AUTHORS**

Dr. R S Bhatia is an eminent chest physician who has been attending national conferences of chest diseases, Tuberculosis as well as bronchology as Chairman /Judge/ Faculty. He has 250 scientific papers to his credit. He has also published 12 medical books. He has been regularly contributing to Medicine updates & Post Graduate Medicine. He has been honored by Indian Chest Society. He has served as national advisory board member of journal of association of physicians of India and also on panel of referees on reputed index journals.

Mohammad Shameem, is working as Consultant, in the department of Pulmonary Medicine since 2005. His field of interest is COPD, Asthma, and interventional pulmonology (He received training in interventional pulmonology from Queen Elizabeth Hospital Sabah, Malaysia, sponsored by Asia Pacific Society of Respiratory Japan; His research work had been published in reputed international journals like Chest, Eur Resp J, Annals of Thoracic Medicine, Respirology.

He received YOUNG SCIENTIST AWARD by Government of UP (3rd Highest Honor in the field of Science and Technology, in UP), beside several other national and international award.

Selected for Fellowship Royal College of Physicians Edinburg FRCP (Edin.).

## PREFACE

Bronchoscopy is a minimalinvasive procedure, whichis safe only in safe hands. Flexible fibreoptic bronchoscopy has emerged as a successful procedure especially in the last decade, both for diagnostic as well as the rapeuticuse, although rigid bronchoscopy remainsa choice procedure in certain indications and also when flexible optic bronchoscopy fails.The advancement in technique with fineness in performance by patient lyper forming adept bronchoscopist has reduced the complication rate to almost zero level. The innovative investigative cum the rapeutic procedures with bronchoscope have reduced hospital stay and offer easy, earlier and better diagnosis, thus allowing earlier and in time the rapeutic interventions to serve the ailing population with broncho pulmonarydiseases.

This humble presentation needs both appreciation as well as constructive critical reading to contribute to futurere vision.

**R S BHATIA**

Consult Chest Physician, Model Town, Ludhiana.

## Contents

1.	AN INTRODUCTION TO BRONCHOSCOPY,	<b>1</b>
2.	INDICATIONS,	<b>2</b>
3.	PROCEDURE,	<b>3-31</b>
4.	CLEANSING, STERILIZATION AND PRECAUTIONS,	<b>32-37</b>
5.	BRONCHOALVEOLAR LAVAGE (BAL),	<b>38-42</b>
6.	TRANSBRONCHIAL NEEDLE ASPIRATION,	<b>43-48</b>
7.	BRONCHOSCOPY LUNG BIOPSY,	<b>49-50</b>
8.	THERAPEUTIC BRONCHOSCOPY,	<b>51-55</b>
9.	RIGID BRONCHOSCOPY,	<b>56-85</b>
10.	ENDOBONCHIAL ULTRASOUND (EBUS),	<b>86</b>

1

## BRONCHOSCOPY

**Introduction:** Bronchoscopy is a procedure which allows the bronchoscopist (usually a pulmonologist or thoracic surgeon) to visualize and examine the patient's airways & lungs, including larynx, vocal cord, trachea and many branches of bronchi. It allows direct view of the tissue and permits to take samples of biopsied lung tissue through the bronchoscope for histological studies in the laboratory. Two types of bronchoscopes are available; a flexible fiber optic bronchoscope and another rigid bronchoscope. For the last four decades, flexible bronchoscopy has taken away almost all the preferential indications from rigid bronchoscopy, because of convenience and patients not requiring general an aesthesia. However, the indication favouring use of rigid bronchoscope in case of massive bleeding as it offers better optics for view and a large suction channel, and in extracting large foreign body or in failure of flexible bronchoscopy are still being kept reserved with rigid bronchoscopy.

Types: A rigid bronchoscopy is straight, hollow metal tube that issued

- When a large tissue sample is to be removed.
- When flexible bronchoscope's view is blocked due to massive bleeding
- When a foreign body such a spiece of food article that cannot be removed by flexible bronchoscopy.

- When a special procedure such as widening (dilating) the airways or debunking or destroying of tumor is to be done using a laser.

A flexible bronchoscopy is along, thin tube that contains many small, clear fibers or a small camera that can transmit light images as it bends. It is a safe and minimally invasive procedure in expert hands and does not require general an aesthesia.

2

## INDICATIONS

Bronchoscopy is done to identify the cause of inflammation and bleeding. It may be indicated to collect secretion from the airways for identifying certain specific abnormality or infection. It may be performed for magnified diagnostic viewing or for collecting samples of biopsied lung tissue to be differentiated histological for diagnosis in the laboratory. It may be used to diagnose and determine the extension of lung cancer. It can be used to find cause of wheeze or difficulty in breathing and also to evaluate previously diagnosed lung cancer & following chest trauma. It may be used to control bleeding, to remove foreign body or thick mucous to clear the blocking airways, to debulk or destroy the in traluminal growth in the airways, and to determine the degree & extent of airways obstruction for placement of stent. It can be therapeutically used to deliver laser treatment, radiation therapy (brachytherapy), or cautery (burning) of the lesion in the airway. Various indications are shown in table-1.

## INDICATIONS OF BRONCHOSCOPY

### A. Diagnostic:

1. Chief indications
  - a. Hemorrhage
  - b. Lung Cancer
  - c. Recurrent infections
  
2. Suspected diagnosis of
  - a. Paralysis of vocal cord
  - b. Stridor
  - c. Localized wheeze d. Pleural effusion
3. Staging of lung cancer
4. Infective etiology such as
  - a. Tuberculosis
  - b. Bronchiectasis
  - c. Lobar Collapse
5. Interstitial lung diseases

### B. Therapeutic:

- a. To clear mucus plugging in airways.
- b. Control bleeding
- c. Palliation of lung cancer
- d. Ablation of tumour
- e. Stenting (bronchial)

Airway management especially in situations like joint alkalosis surgery or in the presence of joint angiosarcoma of oral cavity, lighted styled guided intubation or Ring Adair Elvin

Nasal tube become preferred choice over conventional direct laryngoscope, both in a sleep or a wake patients in anticipated as well as unexpected difficult airways.

**Preparation of Patient:** Patients' preparation includes taking history of any drug intake specially aspirin, history of diabetes, or bleeding diathesis, history of being pregnant (in females) and history of drug allergy to any medication including an aesthetics. Patients are advised and thoroughly explained about the procedure. Routine investigations including chest x-ray are ordered and a consent form is signed. An overnight fast is important and all accompaniments such as contact lenses, dentures, jewellery & wigs are removed. Urinary bladder is emptied and patient is given the hospital gown to wear. Pre medication to help relaxing the patient & drying up the secretion of mouth and respiratory tract is given.

-----  
-----

### PROCEDURE

Patient lies on his or her back on the table; sometimes the procedure is done in a sitting position. Dim light in the bronchoscopic suite allows observing a better image on the video monitor. Intra venous sedative allows the patient to feel relaxed but awake during the procedure. A local spray of local anesthesia is made into the nose & mouth that numbs the throat and reduces the tendency to gag during the bronchoscopic insertion. An anesthetic ointment is applied and slowly, the bronchoscope is inserted and advanced to near the vocal cord, where another spray of an aesthesia is sprinkled and further advanced, with the help of the patient who is asked to make a high-pitch sound, to easily pass the scope through vocal cord. An x-ray machine (fluoroscope) is rightly placed above the patient to transmit the pictures to the video monitor. The bronchoscope is then slowly passed down to larger bronchi.

The air passages are viewed; secretion sample or tissue samples may be collected, by inserting brush or tiny forceps through the scope. Bronchoalveolar lavage with a saline wash may be collected along with tissue biopsy to be sent to laboratory for analysis. In case, Tran's bronchial lung biopsy is required, a small biopsy needle may be used to penetrate the lung through bronchial tube to obtain the sample of the lung tissue from the appropriate site.

For rigid bronchoscopy, general anesthesia is given through end tracheal tube. Muscle relaxant is given and the patient is carefully positioned with neck extended & on ventilating machine to breathe. The bronchoscope is slowly inserted through mouth, into the wind pipe, adjusting the position of the head, as & when required. Tiny brush, forceps or laser can be inserted through the scope. Usually it may take half an hour, but time factor is not important; important is to achieve the target, with minimum of the complications and minimum of patient discomfort. Follow up of the patient is important Post procedural; nil orally is to be strictly observed for at least 2 hours. Spit out salivary secretion is ordered to avoid choking. Avoid harsh coughing for several hours if biopsy has been taken. Patient may cough & gag and complain of discomfort in the chest along with a feeling of tiredness. In case of use of local anesthesia, it may cause bitter taste, dryness of mouth and difficulty swallowing. Sore throat & hoarseness of voice may be observed. 10-20 ml of blood in the sputum is noted. Patient is advised accordingly and always looked for (post-procedure),

- Blood in the sputum more than 20-30 ml.
- Rise in temperature lasting more than 24 hours.
- Having difficulty in breathing.

The procedure is safe but complications such as broncho spasm, cardiac arrhythmias and infection may occur, and require immediate attention. Complications following biopsy such as bleeding, infection including tuberculosis and pneumo-thorax have been reported. The inference of bronchoscopy removed can be normal, or foreign body can be shown or sample of secretions or lung tissue biopsy that has to be sent to laboratory for culture,

## AN INTRODUCTION TO BRONCHOSCOPY

bacteriological & histological decisions. Nil orally till anesthetic effect wears off; a little of water intake may cause choking. Return of gag reflex, checked by placing a spoon on the back part of tongue, means an anesthetic effect is gone.

The procedure as such is a three-hand procedure, where a failure can be faced in the form of difficulty in extending the neck or a nasal bridge fracture, or a failure can be faced when laboratory report is unable to convey definite diagnosis because of inadequate sample and a failure can also be faced when a diagnosis is missed because of needle biopsy had been taken from an inappropriate area.

The physician pulmonologist has to face the horrible situation when he is unable to give final diagnosis after bronchoscopy or a solution to the problem of the patient and he attempts to request for a repeat bronchoscopy. It is always better to enrich your skill with a battery of investigations with plain x-ray & CT scan (must), using electromagnetic navigator to guide to the area of biopsy, to take adequate sample of lung biopsy, to practice a number of times on model-sample before actually performing on the patient & to target to achieve the 100% success and 0% complication rate, using end tracheal ultrasound and virtual CT scan and leaving no chance to say or hear "inconclusive" at the end.

Lung biopsy through bronchoscope is a procedure which is indicated most often in diffuse infiltrative lung disease, tumours, rejection of transplanted lung and in cases where open lung biopsy cannot be performed. It is always kept in mind that the bronchoscopy procedure must be performed with concentration on ensuring the hundred percent outcome in an atmosphere conducive to patient's comfort and with negligible

complications. The satisfaction and success that a bronchoscopist achieves and the relief and comfort provided to the patient, do help in contributing life to extending role of diagnostic & therapeutic bronchoscopy.

Diagnostic bronchoscopy may reveal normal picture, abnormal secretions, hemorrhage, inflammation, obstruction, infection, malignant lesion, airway fistula, stenosis, tracheomalacia, bronchial stump & foreign body and may be utilized for biopsy, BAL or TBNA. The techniques include clearance of secretions and obstruction of airways, bronchoplasty, airway stenting, fistula closure, tumour debulking, laser photocoagulation, bronchial therapy and many more innovative procedures.

-----

-----

**BRITISH THORACIC SOCIETY: RECOMMENDATION  
FOR DIAGNOSTIC FLEXIBLE BRONCHOSCOPY  
(THORAX; 2001; 56 (SUUPLL): I1-I21**

**PATIENTSAFETY**

***Before bronchoscopy***

- Verbal and written patient information improves tolerance of the procedure by the patient and should be provided.
- Patient with suspected chronic obstructive pulmonary disease (COPD) should have spirometric parameters checked before bronchoscopy and, if the COPD is found to be severe (FEV<sub>1</sub> <40% predicted and or SpO<sub>2</sub> <93%), should also have arterial blood gas tensions measured.
- Oxygen supplementation and intravenous sedation may lead to an increase in the arterial CO<sub>2</sub> level and hence sedation should be avoided where the pre-bronchoscopy arterial CO<sub>2</sub> is raised, and oxygen supplementation given only with extreme caution.
- Prophylactic antibiotics should be given before bronchoscopy to patients who are aspheric, have heart valve prosthesis, or a previous history of endocarditis.
- Bronchoscopy should be avoided if possible within 6 weeks of a myocardial infarction.
- Asthmatic subjects should be premeditated with a bronchodilator before bronchoscopy.
- Routine preoperative checks of the platelet count and or prothrombin time are only required in those patients with known risk-factors having routine bronchoscopy without trans bronchial biopsy.

- If it's anticipated that biopsy specimen may be required at bronchoscopy, oral anticoagulants should be stopped at least 3 days before bronchoscopy or they should be reversed with low dose vitamin K.
- On the rare occasion when it is necessary to continue with anticoagulants, the international normalized ratio (INR) should be reduced to < 2.5 and heparin should be started.
- Platelet count, prothrombin time, and partial thromboplastin time should be checked before performing trans bronchial biopsies.
- It is sufficient for patients to have no food by mouth for 4 hours and to allow clear fluids by mouth up to 2 hours before bronchoscopy.
- Intravenous access should be established in all patients before bronchoscopy is commenced (and before sedation, if given) and left in place until the end of the postoperative recovery period.
- Sedation should be offered to patients where there is no contraindication.
- Atropine is not required routinely before bronchoscopy.

***During Bronchoscopy***

- Patients should be monitored by oximetry.
- Oxygen supplementation should be used to achieve an oxygen saturation of at least 90% to reduce the risk of significant arrhythmias during the procedure and also in the postoperative recovery period.
- The total dose of lignocaine (lidocaine) should be limited to 8.2 mg/kg in adults (approximately 29ml of a 2% solution for a 70 kg patient) with extra care in the elderly or those with liver or cardiac impairment.



## AN INTRODUCTION TO BRONCHOSCOPY

- Ligocaine gel (2%) is preferred to lignocaine spray for nasal anaesthesia.
- The minimum amount of lignocaine necessary should be used when instilled through the bronchoscope.
- Sedative should be used in incremental doses to achieve adequate sedation and amnesia.
- Fluoroscopic screening is not required routinely during transbronchial biopsy in patients with diffuse lung disease, but should be considered in those with localized lung lesions.
- At least two endoscopy assistants should be available at bronchoscopy, and at least one of these should be a qualified nurse.
- Routine ECG monitoring during bronchoscopy is not required but should be considered in those patients with a history of severe cardiac disease and those who have hypoxia despite oxygen supplementation.
- Resuscitation equipment should be readily available.

### *After Bronchoscopy*

- Post-operative oxygen supplementation may be required in some patients particularly those with impaired lung function and those who have been sedated.
- A chest radiograph should be carried out at least 1 hour after transbronchial biopsy to exclude a pneumothorax.
- Patients who have been sedated should be advised verbally and in writing not to drive, sign legally binding documents, or operate machinery for 24 hours after the procedure.
- It is preferable that day case patients who have been sedated should be accompanied home and that risk higher risk such as the elderly or those from whom transbronchial biopsy

specimens have been taken should have someone to stay with them at home overnight.

- Patients who have transbronchial biopsies should be given verbal and written advice about the possibility of developing a pneumothorax after leaving hospital.

### *Bronchoscope cleaning and disinfection*

- Compatibility of decontamination methods should be checked with the manufacturers of bronchoscope and accessories.
- Decontamination and disinfection should be carried out at the beginning and end of a list and between patients.
- Cleaning and disinfection of bronchoscope should be undertaken by trained staff in a dedicated room.
- Thorough cleaning with detergent remains the most important initial stage of the process.
- When 2% glutaraldehyde is used for manual and automated disinfection, immersion for 20 minutes is recommended for bronchoscopes at the beginning and end of a session and between patients.
- Longer immersion times of 60 minutes are recommended for known or suspected atypical mycobacterial infections and patients known to be HIV positive with respiratory infections as they may be infected with *Mycobacterium avium* intracellular or other atypical mycobacteria which are more resistant to glutaraldehyde.
- Patients with suspected tuberculosis should undergo bronchoscopy at the end of the list.
- Automated washers disinfectors must be recommended to "minimize staff contact with disinfectants and their fumes.

## AN INTRODUCTION TO BRONCHOSCOPY

- Automated washer disinfectors must have facilities for disinfecting tanks, immersion trays, and all fluid pathways.
- It is essential that sterile or bacteria free water is used for rinsing bronchoscopes, autoclaved or filtered water (using 0.2µm filters) may be used.
- All rinse water pathways (tanks, filters, and pipe work) must be accessible for regular, preferably sectional, cleaning and disinfection.
- Some water-borne mycobacteria such as Mycobacterium chelonae are extremely resistant to glutaraldehyde and a chlorine releasing agent or para acetic acid may have to be used via the water filters.
- A record should be kept of which bronchoscope and other reusable equipments are used on an individual patient and also of the decontamination procedure
- Glutaraldehyde, although widely used for endoscopes, is only slowly effective against mycobacteria. Para acetic acid, chlorine dioxide, and superoxidised water are more rapidly effective (within 5 minutes or less) but are damaging to instruments and processing equipment, are less stable, and are more expensive. They may, however, be less irritant than glutaraldehyde.

### *Staff safety*

- All staff should be vaccinated against hepatitis B and tuberculosis, immunity and tuberculin status should be checked as appropriate.
- During bronchoscopy staff should wear protective clothing (gowns or plastic aprons, masks and gloves).

- High grade articulate masks should be worn when patients known to have multi drug resistant tuberculosis or those at high risk undergo bronchoscopy and the procedure should be carried out in a negative pressure facility.
- Non- powdered latex or non-latex gloves should be worn instead of powdered latex gloves.
- Injection needle should not be re-sheathed, and spiked biopsy forceps require careful cleaning.
- Pre- employment health checks should be carried out on all staff working with aldehydes according to COSHH recommendation, and regular periodic screening with regard to lung function and occurrence of symptoms should be carried out by occupational health department.
- Bronchoscopes should be disinfected ideally in a dedicated room using ventilated automated systems, preferably inside a mine carbine, to prevent unnecessary exposure to disinfectants.
- During cleaning and disinfection staff need to wear protective clothing (sterile gloves and plastic aprons with eye and respiratory protection, where appropriate) to protect them from splashes, aerosols, and vapor.
- The use of disposable accessories, especially injection needles, may reduce the risk of infection which may occur during the cleaning of equipment.
- Wherever possible, autoclavable or disposable accessories should be used to prevent unnecessary exposure to disinfection.

Bronchoscopy staff needs to be trained in patient care, infection control and instrument decontamination including the safe use of aldehydes and the potential health risks.

**Bronchoscopy in the intensive care unit (ICU)**

- The internal diameter of the endotracheal tube, through which the bronchoscope is inserted, must be taken into consideration before bronchoscopy.
- Intensive care units should have the facility to perform urgent and timely flexible bronchoscopy for a range of therapeutic and diagnostic indications.
- Patients in ICU should be considered high risk from complication when undergoing fiberoptic bronchoscopy. Continuous multi-modal physiological monitoring must be continuous during fibroptic bronchoscopy.
- Care must be exercised to ensure adequate ventilation and oxygenation is maintained during fibroptic bronchoscopy via an endotracheal tube.
- More profound levels of sedation anaesthesia can be achieved in ventilated patients provided the clinician performing the procedure is acquainted with the use of sedative' anaesthetic agents.

***Standard and performance of diagnostic technique***

- At least five bronchial biopsy specimens should be taken in cases of suspected bronchial malignancy.
- Biopsies, brushing and washings should all be obtained in cases of suspected endobronchial malignancy.
- A minimum diagnostic level of at least 80% should be obtained from a combination of biopsies, brushing and washing in cases of endoscopically visible malignancy.

- When taking tranbronchial lung biopsy specimen in patients with diffuse lung disease, an attempt should be made to obtain 4-6 samples from one lung.

***Patient care***

- Verbal and written patient information improves tolerance of the procedure and should be provided.
- It is sufficient for patient information improves tolerance of the procedure and should be provided.
- Patients, who have been sedated, should be advised not to drive, sign legally binding documents, or operate machinery for 24 hours after the procedure.


-----  
-----

**BRONCHOLOGY IN INDIA  
THE SPECIALISTS ARE CONVERGING**

Respiratory medicine was meant only to anti tuberculosis treatment in middle of 20th century. The interest in non-tubercular diseases gained importance and created chest speciality as a separate entity. Many reports were published on non tubercular respiratory disease and the interest arose in visualizing bronchial tree, creating a rigid bronchoscope. The fiberoptic properties of glass fiber opened a new era of flexible fiberoptic bronchoscopy. In 1964, Ikeda performed first fiberoptic bronchoscopy, Europe recognized its value in 1974, and India accepted the technique in 1976. Dr. Sarkar was the first surgeon followed by Dr. Shah in 1980 and 1982 respectively to use bronchoscopy. The non-invasive visualization of bronchial tree mainly for diagnostic purpose became popular and in no less than five years, data started pooling in from various centers in India. The approach was found to be safe and rewarding, being done under local anaesthesia. This involved many facets about the procedure, its safety, complications, outcome data, cleaning and care of instrument and cost effectiveness. This was followed by it's extending role as therapeutic bronchoscopy in OPD as well as in intensive care pulmonary units, in patients with or without ventilation and with PEEP. Thus flexible bronchoscopy has accessed its important mandatory application on patients in the intensive care units.

The widening of scope and application of a battalion of appliances through fiberoptic bronchoscope further improved it's utility and stimulated many surgeons, chest surgeons and pulmonologists to share a platform to create this subspecialty of bronchology in India

in the last decade. The joint efforts have been able to achieve, through creation of a society, the regular update and training through workshops and conferences, allowing many to learn and teach, training so many, creating centers of this subspecialty and allowing transglobal interaction. The move has been spotted and very well recognized to evolve recognition of this subspecialty in respiratory medicine as a super specialty by National Board of Education in the same spirit and standards, the fellowships are being offered abroad. Let the flow of knowledge flows uninterrupted! Bronchology in India is exponential in growth consistent with mottos of enhancement of skill and knowledge through interaction and practical hands on actual "how to do it"



**BRONCHOSCOPY IN INDIA  
THE PACE IS SLOW. CAN IT BE IMPROVED?**

Fiberoptic bronchoscopy has achieved in as much short time as one would not dream. The progress is fast progressive in the west; the Indian scene is at a slow pace. The factors responsible and the reasons contributing to its tortoiséd pace and the possibilities to improve the present pace are briefly discussed.

It is almost second decade when the services of fiberoptic bronchoscope were pressed to be utilized in Indian hospitals. In earlier days, those worked mostly with bronchoscope were from the surgical specialty. The performance was in itself an achievement par excellence, providing non-surgical intervention to achieve what could have not been possible to expect from a surgeon to do without knife. The trend was set in and since the chest specialty was also in its infancy in those days, many physicians hesitantly gathered courage to come forward to opt for performing certain diagnostic bronchoscopies, at a few selected centers. The recognition of chest specialty brought forward many chest physicians trained in bronchoscopy and the scope of bronchoscopy widened, as many of them attending various workshops and conference could taste the beneficial advantages of this noninvasive technique, expressed their curiosity and willingness to perform the bronchoscopy. As the bronchoscopy in the world was advancing with leaps and bounds, extending its diagnostic and therapeutic indications, the air of beneficial therapeutic advancement reached the Indian soil and many centers, especially the private hospitals, actually pressed their pulmonologists to perform, to succeed, to eventually emerge as bronchoscopists. The ink thus sprinkled got disseminated into the

Indian Sea and many centers were seen all over India, performing with bronchoscopy, utilizing its role in various diagnostic and therapeutic indications. Chest societies came into being and society of bronchoscopists of India emerged. The main drawback in gathering pace in utilizing this fine, ever challenging, non interventional procedure was the economical factors, lack of proper training, lack of infrastructure, lack of trained staff lack of proper centers, lack of referral system, lack of evaluation of outcome and existence of professional jealousy Considering these factors one by one, poverty plagues the people since centuries, and lack of education (illiteracy) adds to the agony of innocent and ignorant people. Most of the population resides in rurality and go the primary health centers where basic medical requirements are poorly met with, the advanced facility still remain as a distant dream. The provision of bronchoscopy by local government in public hospitals is lying unused due to lack of specialists. The people doing bronchoscopy in centers are doing because their services are pressed only for the same, irrespective of the outcome because there is no evaluation data of success rate and complications of bronchoscopic performance. And those who done a large number of case are not getting sufficient referral for lack of knowledge to fellow colleagues or because of financial burden restraint that exists. And still, many who are adept in using bronchoscope are working at junior level and their heads who are chest-masters of grey days and no minimum of performing in bronchoscopy suite, are over- impressing their skill due to professional jealousy and don't allow the right bud-root to grow into a yielding plant.

The solution lies in creating proper centers, with good infrastructure, backed up with proper trained staff, allowing

skilled bronchoscopists to work with always yielding successful bronchoscopy both diagnostic and therapeutic, along with training the young bronchoscopy and are able to run independent bronchoscopy suites with near total successful performance and side by side collection the data, for self assessment as well as for future research. This systemic measured approach shall be sufficient to add progressive pace to the paws of bronchoscopy in India which is eagerly looking to attain rehabbitarian jump from the tortoisid pace

-----  
-----

## DIAGNOSTIC INDICATIONS OF BRONCHOSCOPY

**Introduction:** Bronchoscopy has attained a respectable place as a diagnostic tool in respiratory medicine on the last few years. The success rate is quite high and the patient's safety is 100% ensured in safer hands. This is used:

1. To asses airway and airway patency.
2. To evaluate lung lesion, undiagnosed on chest x-ray.
3. To obtain tissue biopsy for diagnosing underlying lung disease.
4. To search for focus of suspected or positive sputum cytology.
5. To stage lung cancer and to evaluate treatment.
6. To find out cause for unexplained cough, stridor, wheeze or bleeding.
7. To obtain microbial sample to diagnose infection aetiology.
8. To evaluate problems related to endotracheal tube.
9. To evaluate airway injury, thermal, chemical or mechanical.
10. To find out vocal cord paralysis.

**Nosocomial Pneumonia:** Diagnostic bronchoscopy to obtain accurate pathogens from lower respiratory tract in acutally ill hospitalized patient in ICU for prompt and appropriate antimicrobial treatment in noscomial pneumonia is rewarding. Specimen sampling can be obtained by bronchoalveolar lavage for increasing the sensitivity & specificity of the diagnostic yield. This is extremely important because a rising incidence of 9-25% of nosocomial pneumonia has been observed in patients on ventilators in intensive care units and a rising mortality of 35-

## AN INTRODUCTION TO BRONCHOSCOPY

90% can be brought down by promptly initiating the treatment. So, prognosis is highly dependent on accurate diagnosis of the pathogens responsible.

### **Bronchoscopy in sputum smear negative TB**

Bronchoscopy is successfully used in endo bronchial and pulmonary tuberculosis where yield for sputum smear AFB is much enhanced. Nevertheless sputum negative TB cannot be diagnosed by sputum microscopy as the number of AF bacilli is less than 10,000 bacilli per ml of sputum. For every 10 sputum smear positive cases, there are at least 4-12 sputum smear negative cases. However, transmissions from infection of smear negative tubercular are about 22% of smear positive cases.

Mycobacterial cultures, serological tests, nucleic acid amplification, detection of mycobacterium tuberculosis specific antigen are offered investigations. Fibreoptic bronchoscopy with washing, brushing offers higher diagnostic value as compared to smear & culture testing. 25-50% cases can be diagnosed by biopsy offer additional diagnostic usefulness and also occludes atypical presentation of other non-tubercular diseases.

**Haemoptysis:** Bronchoscopy is wonderful diagnostic tool in haemoptysis which has varied aetiology and diagnostic accuracy which would change the therapeutic option. In a descending order of frequency, the cause of haemoptysis has been bronchogenic carcinoma (nearly 1/3rd of cases), bronchitis (nearly 1/4th of cases), idiopathic (more than 1/5th of cases), bacterial pneumonia (more than 1/10th of cases) and tuberculosis (more than 1/20th of cases).

**Lung cancer:** Bronchoscopy helps in diagnosing lung cancer, providing information of lung cancer staging at the same time.

Stage T1- Tumour within the airways, less than 2cm from the carina.

Stage T2- Bronchial obstruction greater than 2cm away from carina, and has associated atelectasis.

Stage T3- Main bronchus involved but greater than 2cm away from carina.

M1- Tumour lets in the trachea or opposite airway.

T4- Ipsilateral submucosal tumourlets within same airway.

T4- Tumour invasion of carina and/ or trachea.

Lung cancer can be diagnosed upto 90% if the lesion is visible. A yield of 80% can be achieved by bronchoscopic needle aspiration in case of submucosal or peribronchial carcinoma. A lower yield of 60% is obtained in peripheral tumours, a combination of sampling techniques such as brushing and lavage or using forceps and fluoroscopy, and BAL after biopsy attempt help in improving the diagnostic yield. Diagnostic yield of BAL is more than half of the cases in adenocarcinoma, small cell carcinoma, lung metastases but more than one third in squamous cell carcinoma. Brush & lavage give diagnostic yield in more than 3/4th of case of squamous cell carcinoma, adenocarcinoma, small cell carcinoma but nearly half of the patient in lung metastases.

**Bronchoscopic Lung Biopsy:** This offers diagnostic yield in almost 3/4th of the cases in squamous cell carcinoma, small cell carcinoma, lung metastases and more than half of the cases in adenocarcinoma.

## AN INTRODUCTION TO BRONCHOSCOPY

Diagnostic bronchoscopy thus helps in detecting endobronchial abnormalities through BAL for both infection & biopsy for both visible & bronchoscopically invisible parenchymal lung lesions. Bronchoscopic needle aspiration of paratracheal, subcarinal or perihilar lymphnodes is useful in diagnosing and staging of thoracic malignancies. The technique is also useful in diagnosing endobronchial, submucosal and even peripheral nodules and masses. Even bronchogenic or mediastinal cysts adjacent to major airways can best be obtained by bronchoscopy. Bleeding, infection haemomediastinum and pneumothorax are common complication. Severe bleeding is rare. Damage to the inner lining of bronchoscope by inadvertent passage of the needle is quite expensive.

Certain other diagnostic procedures that are bronchoscopically performed are briefly given.

**Auto Fluorescence Bronchoscopy:** It is useful in detecting early mucosal malignant lesions. Bronchial mucosa when illuminated via bronchoscope, gives higher fluorescence, which is decreased when there are malignant cells, especially intraepithelial lesions. When green light, as compared to routine white light is used. Blue light has been used for magnified bronchoscopy to detect pre-malignant lesions.

**Bronchoscopic Ultrasound:** This technique is used to visualize via ultrasound, the extra airway structures which could not otherwise be seen bronchoscopically. For better, to the point, and meaningful imaging, modification in the form of water-inflatable balloons within the bronchoscope to permit constant 360 degree circumferential contact ultrasound probe and airways wall has

been utilized. Endobronchial ultrasound (EBUS) device can be inserted through flexible bronchoscope into the airways for exploring airways, mediastinum and the lung. This is minimal invasive procedure, done under local anaesthesia for looking and assessing tumour invasion, TBNA guidance & differentiating vascular from nonvascular structures. EBUS- TBNA is a safe and accurate diagnostic interventional bronchoscopy with a very good diagnostic yield. EBUS is quite useful as an adjuvant to brachytherapy and photodynamic therapy in assessing tumour volume and other interventions such as airway recanalization. The sensitivity of white light bronchoscopy for detection of severe dysplasia and cancer is in little less than 2/3rd of cases. The laser induced fluorescence endoscopy enhances its sensitivity in upto 90% of cases, showing total fluorescence intensity from tumour sites lesser than that from normal sites, Therefore, endobronchial ultrasonography is useful in determining the depth of tumour invasion into the bronchial wall, thus helping early detection of precancerous lesions/cancer in sites and further helping in deciding photo dynamic therapy for patients with central-type of early lung cancers. It is indicated in suspected lung cancer by abnormal sputum aetiological findings, inspection for synchronous tumours, surveillance following cancer resection and primary screening among high-risk patient. Contraindication essentially do not differ from routine bronchoscopy and no untoward risks reported in using autofluorescence bronchoscopy. 20 performances in a supervised setting provide basic competency which is maintained by 10 procedures per year.

**Virtual bronchoscopy:** This provides three dimensional reconstruction of the endobronchial anatomy to understand relationship of airways in relation to other structures and



intrathoracic organs. However, standard bronchoscopy is required to obtain tissue sample for histological diagnosis, as virtual bronchoscopy is not able to differentiate between benign and malignant lesions.

Bronchial asthma: Airway wall thickening from edema & inflammatory cellular infiltration and from structural changes such as hyperplasia of mucous glands, reticular basement membrane thickening, vascular proliferation and hypertrophy/hyperplasia of smooth muscles of airways has been revealed by bronchial biopsy. BAL has confirmed that the characteristic inflammation in asthmatic airway occurs as a result of changed T-lymphocyte response, with enhanced production of cluster of cytokines enclosed on chromosome 5932-34 (interlukins 3,4,5,9,13 and GM-CSF) involved in the generation of IgE and the recruitment as well as activation of mast cells, eosinophil & basophil. Also, these studies have revealed that persistent epithelial cell loss in bronchial asthma is due to apoptosis (oxidant induced premature prolonged cell death) and not due to cytotoxicity of released inflammatory products, as generally thought. Therapeutic role of BAL in asthma includes clearing of mucous plugs which are responsible for hypoxemia especially in acute asthma.

-----  
-----

### **NON-YIELDING BRONCHOSCOPY- WHERE LIES THE CAUSE? (FAULT)?**

Fibreoptic bronchoscopy has revolutionized the pulmonary medicine in the recent times. The bronchoscopic armamentarium provides almost every facility to utilize for diagnostic yield of bronchial, peribronchial, bronchopulmonary and mediastinal lesions. Unlike gastrointestinal endoscopy, fibreoptic bronchoscopy doesn't allow any place for repeat bronchoscopy following a non yielding bronchoscopy. And if a bronchoscopist, despite availability of a variety of valuable accessories faces a failure and then dare to request the patient for repeat bronchoscopy, the experience is most embarrassing to face the horrified face of the patient. Where lays the cause for such a non-yielding bronchoscopy?

The bronchoscopist must select his patents carefully and order the investigations most judiciously e.g. ordering the radiological investigations such as plain film PA view, tomography, bronchoscopy and CT scan without even giving a word of thought is highly unwanted of bronchoscopist. Many a times a sensitive radiologist's opinion may negate the need for the other investigations, and even bronchoscopy sometimes those who don't give importance to analyzing and proper reporting of plain x-ray chest, should search sensitivity among themselves. Unnecessary exposure to radiation and for getting no benefit to the patient should impress upon the doctor to not order such an investigations. Tomography and bronchoscopy should be removed from the list of routine investigations. Similarly ordering of investigation should be followed by proper and critical analysis of the radiological reports e.g. x-ray for a lateral or other view in

## AN INTRODUCTION TO BRONCHOSCOPY

case of doubt may be rewarding many a times, and doctor should not hesitate in asking for, if deemed fit. Discussing the reports with radiologist and trained staff prior to proceed with bronchoscope and maneuvering it properly to an appropriate position for achieving the yield to near total success, is always fruitful. This need to be done for each bronchoscopy.

What is most important is to review the reports and conducting sessions of multiple practice manipulating performances on ling model in demonstration room by the bronchoscopist and trying to device the various modalities and ultimately deciding the strategies of management in those situations if arise during bronchoscopy and their getting first hand information before actually performing on the patient. This not only adds confidence to the bronchoscopist, but makes him prudent to promptly act appropriately on facing the unexpected situation and utilize all his battalion of instrumentation to make it a high yielding intervention and ultimately save him to avoid cutting a sorry figure at the end of the day. Thus, the yield can be improved to near total through self preparing for each patient, interacting with radiologist and trained staff and pre-planning for using the appropriate instrumentation through bronchoscope. To reach to an appropriate target, use of electromagnetic navigator has been very useful to improve the bronchoscopic yield. Many a times the expected fairly well bronchoscopy becomes non-yeilding due to unexpected complications such as tracheal perforation or vascular injury, can well prevented by using endotracheal ultrasound that allows to observe different layers of bronchial wall, the depth and degree of penetration of tumour infiltration (specially during tumour resection) and the adjacent mediastinal structures upto 4 distance. The area of bronchus beyond the area of obstruction (especially of

the length of stenosis for deciding the stent length and the extraluminal hilar or mediastinal areas can very well be observed by spiral CT scan called virtual bronchoscopy. This improves the bronchoscopy yield, as the site of transbronchial needle aspiration biopsy is best targeted. Well in time utilization of these bronchoscopic accessories can make every performance high yield-bronchoscopy. What is required to follow the stepwise guidelines to make it success story every time you do it!

-----  
-----

## **RADIATION EXPOSURE DURING BRONCHOSCOPY**

Fluoroscopic imaging is forms an essential part of bronchoscopy. It is required during diagnostic and therapeutic bronchoscopic procedures such as fluoroscopy guided cytology brush specimen from endobronchial, transbronchial needle aspiration, transbronchial biopsy, brachytherapy, airway stenting etc. Radiation exposure to the bronchoscopist as well as accompanying personnel becomes hazardous as the number of working hours go on increasing despite use of protective measures/precaution. The risk is more to the supporting staff, as they are not much literate-trained against the consequences of cumulative effect of radiation in bronchoscopy suite. Their protection and safety form an integral part of the duty of the incharge bronchoscopist. They must be assessed regularly for effective dose equivalent. The degree of tissue damage is directly related to type and quantity of radiation and individual tissue susceptibility to radiation damage. A rough estimate shows less than 1% of all breast cancers and almost 1% of all leukemias are the result of diagnostic radiation. Other effects include erythema, necrosis, desquamation, bone marrow suppression, organ atrophy, fibrosis, cataract, sterility, genetic risk and cancer.

**Occupational hazard:** Occupational hazards account for 20% of radiation exposure created artificially for diagnostic procedures. The safety committee has fixed the upper limit of safe radiation exposure over 5 years of period as 2 rem per year, with further limit of exposure not exceeding 5 rem in any single year. However, the accumulated maximum permissible dose should be less than 1 rem per year of life. The radiation exposure has been

reported in various physicians and surgeons of different specialities; however the exact data for radiation exposure to bronchoscopists and their staff personnel has not yet been obtained. Even then, the issue is hot and assumes its significance without doubt as bronchoscopy is extending its scope and area of operation.

How to protect: The advantage and benefits to the patient outweigh the risk to the patient. But the exposure is always kept as low as reasonably achievable. This ultimately limits the radiation exposure to the staff. Adjustment of field size, the intensity of beam and penetration of radiation and appropriate collimation significantly reduce the quantity of scattered radiation. This is further cut down if the image intensifier is kept as close to the patient as possible.

If health personnel kept the distance from the patient twice that of source of radiation to the patient, chances of radiation are reduced by one fourth, since radiation intensity is inversely proportionate to the square of the distance. Other people, who are not directly involved, should keep maximum distance whenever the fluoroscopy is being used. Further the time used for fluoroscopy should be reduced. Protective lead aprons and shielding devices should be used. Thyroid collars must be worn to avoid the risk of developing thyroid cancer. This is often not used out of carelessness. It must be kept in mind that its use protects the thyroid gland at least by 10 fold. Similarly, 0.6 mm lead glasses do help to reduce the risk of cataract by 6-8 times. However, the heavy weight of glasses becomes an obstacle for their use at least for an extended procedure. Presently, no data is available as yet for the risk of radiation exposure to bronchoscopists.

## AN INTRODUCTION TO BRONCHOSCOPY

Chief of bronchoscopy suite must ensure wearing of all these protective measures and an annual checking of all these measures including lead aprons must be done for any defect or damage due to wear and tear.

Evaluation and monitoring: Radiation exposure can well be monitored by film badges and thermo luminescent dosimeters. Electronic dosimeters, even with alarm facility are also available, but they do not provide cumulative radiation exposure reading value. A single badge is generally worn at the neck; the area, which is usually not covered by lead apron and EDE, is calculated by dividing the radiation reading by 5.6. The radiation exposure dose must be checked monthly, without any laxity to avoid legalities as well health hazard to the person working in bronchoscopy lab. Any abnormal finding must be backed with regular checkup and investigations. And a temporary stay back from duty or shifting the staff from the bronchoscopy suite to other duty with no radiation exposure has to be done without delay.

Let me state that the increasing use of radiation involvement in bronchoscopy should not abandon the use of fluoroscopy in bronchoscopy procedures. What is required is that we need to follow the guidelines strictly. The quality control of fluoroscopy equipment and services of radiation physicist must be pressed at least for initial period of few months to periodically calibrate the equipment. Those working, as a close assisting group to bronchoscopist, must be disseminated knowledge about the radiation exposure, it's risk and measure of protection as a part of their training schedule. A set of preliminary guidance and

consensus report must be published regarding the radiation to the people working in bronchoscopy suit.

-----  
-----

## FIBEROPTIC BRONCHOSCOPY AND BRONCHO PULMONARY INFECTIONS

Fiberoptic bronchoscopy allows direct vision of airways and enables the identification of characteristic changes associated with disease process. Evaluation of bronchoscopic samples provides early identification of pathogenic organism contributing to early treatment and favorable outcome.

### **A. Pulmonary Infections in Immunocompromised Host:**

Bronchoscopy is probably the safest of the invasive pulmonary diagnostic procedure for diagnosing pulmonary infections in immunocompromised patients as the expectorated sputum do not necessarily reflect the lower respiratory tract flora because of contamination by micro-organisms in the upper airways. Patients commonly presenting with this diagnostic problem include patients with HIV infection, AIDS, congenital immunodeficiency syndrome, malignancy (including lymphoma, leukemia), receiving cytotoxic chemotherapy and patients on long term corticosteroid therapy (including organ transplant patients). However bronchoscopy may not be a high priority procedure for the routine work up for such patients in India.

**B. Pulmonary Tuberculosis:** Patients suspected of having active tuberculosis in whom M. Tuberculosis is not demonstrated in sputum smear or from whom sputum cannot be obtained, pose a difficult diagnostic and therapeutic problem. In patients suspected of having miliary tuberculosis TB mediastinal lymphadenopathy or endobronchial tuberculosis, bronchoscopy can be of help in confirming the diagnosis of tuberculosis and

excluding other diseases. Bronchoscopy is also very useful in diagnosing pulmonary tuberculosis in children. Peculiar problems encountered in bronchoscopy for suspected tuberculosis include the inhibitory effect of local anesthetic agents on M. tuberculosis and transfer of infection from one patient to another by the fiberscope. Lignocaine is the least inhibitory agent but should be used sparingly if specimens for M. tuberculosis are being collected and disinfection of the fiberscope after use with 2% glutaraldehyde for at least 30 minutes. Atypical Mycobacteria can also be diagnosed reliably by staining and culture of BAL specimen.

- c. Fungal Infection:** Bronchoscopy with BAL has low yield in fungal infection especially in invasive Aspergillosis, the yield being about 50%. Yield can be increased by doing transbronchial biopsy or transbronchial needle aspiration.
- d. Viral Infection:** Viral infection can be diagnosed reliably by BAL. The sensitivity for detecting viral material can be increased using special techniques (monoclonal antibodies, polymerase chain reaction,) culture of BAL and transbronchial biopsy.
- e. Pneumocystic Carinii Infection:** P. carinii cannot yet be cultured in vitro. Sputum smear examination by Giemsa stain, methanamine silver stain and immunofluorescent staining, the organisms can be identified in up to 80%, upon the experience of laboratory. Bronchoscopy with BAL/TBB can be done either routinely in all patient suspected of having P. carinii infection whose sputum specimens are non diagnostic or in

those patients only, who have no response within five days of empirical therapy. The yield of BAL is more than 90%.

**f. Bacterial Pneumonia:** Bacterial pneumonia has been a difficult entity to assess microbiologically as the causative organisms is recovered from the sputum in less than 60% of cases and it is influenced by adequacy of specimen and contamination. BAL had a diagnostic sensitivity of 100% for bacterial pneumonia and 88% for all lower respiratory tract infection and specificity of 100%. Fiberoptic bronchoscopy can also be useful in diagnosing pulmonary actinomycosis.

**g. Bronchiectasis and Lung Abscess:** Endobronchial examination with a Fiberoptic bronchoscope in case of localized bronchiectasis can be done to exclude foreign body, tumor, or tubercular stricture. Bronchoscopy can also help in deciding the infecting organisms in patients of bronchiectasis and lung abscess who do not respond to usual antibiotics. Selective bronchography can also be done in patients of bronchiectasis through fiberoptic bronchoscope.

-----  
-----

## SPECIMEN COLLECTION

The specimens are obtained from the lung segment with a new infiltrate based on chest X-ray or the segment that upon inspection has purulent secretion. In patients without radiographic densities, the right middle lobe or the lingual is to be chosen as the sampling area. The range of specimens needed varies with the clinical problem and the local range of skilled laboratory service available. Usually a combination of specimens is required to increase the yield.

**1. Brush cytology and protected Brush specimen (PSB):** Only those types of cytology brushes, which have a protective sheath, should be used. The ordinary single sheathed brush is inadequate. Contamination by Nasopharyngeal commensal organisms occurs too frequently. Wimberley et al (1979) has suggested that double catheter with a distal plug is not contaminated by upper airway organism. For optimal results, topical analgesia should be applied without injecting into the bronchoscopic channel i.e. aerosol or nebulized lignocaine may be preferred. No suction should be applied before taking specimens. Smear should be prepared on glass slide immediately to avoid drying and should be stained for various bacteria, fungi and cytology (neoplastic cells & inclusion bodies). The brush can also be agitated in 1 ml of sterile ringer lactate solution and this fluid is used for direct plating on to several media e.g. blood agar, Sabouraud-dextrose agar (fungi), Mac Conkey's (intestinal organism), Lowenstein Jensen (M. Tuberculosis), slopes and tissue culture (for viruses).

2. **Bronchial Washing:** Usually 5-10 ml. of 0.9% saline is instilled with each wash and about 25-50% of this can be aspirated into the trap. A yield of 5-10ml. of aspirate is usually sufficient. Culturing the trap specimen for bacteria other than Mycobacteria is not helpful because contamination with nasopharyngeal secretions occur in majority of cases.
3. **Bronchoalveolar Lavage (BAL):** BAL should be performed in the affected segment preferably other than that from which selective culture and brush biopsy have been taken. Sterile buffer saline is infused in 50ml. Aliquot to a cumulative amount of 200 to 300ml. The fluid is aspirated with low-pressure suction (50-100 mm Hg) after each aliquots of fluid inserted. They can be kept at room temperature instead of Ice if transported to the lab within an hour with no loss of viability neither in the cells nor over growth from contaminating bacteria. BAL fluid is examined for total and differential cells count, protein estimation, enzyme estimation, cytological examination and quantitative culture.
4. **Protected Bronchoalveolar Lavage (PBAL):** Protected transbronchoscopic balloon tipped catheter should be used which has two lumens, the larger one for irrigation and aspiration and the smaller one communicates with the latex balloon at the distal end of the catheter and allows optimal occlusion at the level of the third generation bronchi. Protective specimen brushing and protected BAL has specificity of 92% for protected specimen brushing and 97% for protected BAL.

5. **Biopsy:** Endobronchial biopsy is taking visualized lesion and histopathological diagnosis can be made immediately. When the lesion is in a segmental or subsegmental bronchus or distal to a bronchial stenosis it can be biopsied with a curette.

Transbronchial lung biopsy can also be done to diagnose lung infection but a clotting screen must be performed before it. Platelet count should be more than 1 lac/cumm and bleeding time, clotting time prothrombin time and prothrombin concentration should be normal. Ideally TBB should be performed with fluroscopic control and should always be confined to one lung because of the risk of inducing bilateral pneumothorax. If the disease process appears to be unilateral on X-ray, the segment with the highest density of shadow is chosen for the site of biopsy. With the bilateral extensive disease the lateral segment of the right lower lobe is selected. Usually 4-6 specimens are taken. Specimen obtained should be fixed in a 10% formaline solution and it should be 2 mm in diameter and float in the fixative indicating that they include alveolar tissue. Occasionally consolidated lung will sink. A chest X-ray should be done routinely after TBB to rule out pneumothorax. In diagnosing infectious agent by bronchoscopy protected specimen brushing should be taken before protected BAL & finally biopsy specimen should be obtained if indicated. Using transbronchial biopsy the positive diagnostic yield in infection between 47% & 91% has been reported.

Transbronchial needle aspiration can be done to sample mediastinal lymph node in tuberculosis and fungal diseases.

-----  
-----

### BRONCHOSCOPE-CLEANSING, STERILIZATION AND PRECAUTIONS:

The standards of cleanliness used for fiberoptic bronchoscopy have changed with time. It is very essential to follow strict cleansing, sterilization and universal precaution to prevent cross infection to other patients health care personals.

1. **Cleansing:** It should be done using a detergent antiseptic solution, clean water and 50%-70% alcohol as usual.
2. **Sterilization:** All bronchoscope, biopsy forceps and other instruments should be totally immersible and following routine cleansing, they should be sterilized by 30 minutes immersion in 2% glutaraldehyde. A syringe is used to suck the solution into the aspirating channel and is left attached to ensure continued contact with the solution during the period of immersion. The instrument subsequently must be washed & irrigated in sterile water before use.
3. **Precaution During Procedure:** Assuming all patients to be potential cases, following precautions should be taken routinely in all bronchoscopies to limit potential infection to staff and other patients.
  - a) The bronchoscopist and assistant should wear disposable or washable gowns, disposable gloves and eye protection in the form of close fitting spectacles of goggles. The Operator must

wear a surgical mask to prevent contamination by droplet infection into the mouth.

- b) All detritus including swabs collected during bronchoscopy should be disposed of properly, taking it to be potentially infective.
- c) All contaminated surfaces should be cleaned with a 10% solution of house hold bleach (sodium hypochlorite).
- d) Specimens obtained at bronchoscopy should be packed carefully and labeled "high risk of AIDS" if a procedure is done in immunocompromised host.
- e) Lignocaine should not be injected into the area, which is to be sampled as it may inhibit the growth of some bacteria but probably not *M. tuberculosis*.
- f) It is desirable to use the totally immersible newer generation instruments for proper sterilization.

### REFERENCES FOR FURTHER READING

1. Daby CL, Mugusi F, Chen LL, Schmidt DM, Small PM, Beare E, Aris E, Mtoni IM, Cegielski JP, Lallingar G, Mbaga I, Murray JF Pulmonary complications of HIV infection in Daress Salaam. Tanzania; role of bronchoscopy and bronchoalveolar lavage. *Am J. Respir Crit Care Med* 1996; 154: 105-10.
2. Roussell MD, Torrington KG, Teholder MF. A ten year experience with fiber optic bronchoscopy for Mycobacterial isolation. *Am Rev Resp Dis* 1986; 133:1069071
3. Sarkar SK, Sharma GS, Gupta PR, Sharma RK. Fiberoptic bronchoscopy in the diagnosis of pulmonary tuberculosis. *Tubercle* 1980; 61:97-99



4. DE Blic J, Azevedo I, Burren C P, Le Bourgeois M, Lallemand D, Scheinmann P. The Value of flexible bronchoscopy in childhood pulmonary tuberculosis. Chest 1991; 100:688-692.
5. Baughmann RP, Dohn MN, Loudon RG, Frame PT. Bronchoscopy with BAL in TB and fungal infection. Chest 1991; 99:92-97.
6. Gracia JD, Miravittles M, Mayordom C, Ferrer A, Alvarez A, Bravo C, Vendrell M. Empiric treatments impair the diagnostic yield of BAL in HIV positive patients. Chest 1997; 111:1180-6
7. Teague RB, Wallace RJ Jr, Awe RJ. The use of quantitative sterile brush culture and gram stain analysis in the diagnosis of lower respiratory tract infection. Chest 1981; 79:157-61.
8. Wimberley NW, Bass JB Jr, Boyd BW, Kirkpatrick MB, Serio RA, Pollock HM. Use of bronchoscopic protected catheter brush for the diagnosis of pulmonary infections. Chest 1982; 81:556-62.
9. Hsieh MJ, Shieh WB, Chen KS, Yu TJ, Kuo HP, Tsai YH. Pulmonary Actinomycosis appearing as a "ball in the hole" on chest radiography and bronchoscopy. Thorax 1996; 51:221-2.
10. Meduri GU, Beals DH, Maijubi AG, Baselski V. Protected BAL a new technique to retrieve uncontaminated distal airway secretions. Am Rev Resp Dis 1991; 143:855-64

-----  
-----

## FIBEROPTIC BRONCHOSCOPY PAST, PRESENT AND FUTURE

The lurch to visualize bronchial tree created the rigid bronchoscope, Guastav Killian invented it in 1897. The fiberoptic property was utilized and Shigeto Ikeda performed the first flexible fiberoptic bronchoscopy in 1964. In 1974, the Europe and in 1976, India accepted it's medical value. This was followed by aggressive utility of diagnostic as well as therapeutic bronchoscopy as a safe and minimally invasive procedure in the respiratory medicine. The basic principles are kept tightly in place; the skilled bronchoscopists refine their techniques and excel in their therapeutic procedures while the trainees are stretchier to learn with total perfection, thus creating an atmosphere of carrying out perfect bronchoscopy for the future. Transbronchial needle aspiration by Wang in 1978 allowed taking submucosal samples of tracheo-bronchial tree for cyto and histopathological studies. In 1978 Toty introduced Nd : Yag laser. This became popular of airway, and using laser a therapeutic measure in cases such as micro-invasive malignant melanoma. Many alternatives are available for debulking intraluminal growths.

For strictured or compressed blocked airways, for sealing fistulae and to support weakened cartilage, Dumon introduced silicon tracheobronchial stents in 1987. To improve the existing outcome of 30% diagnostic yield for better detecting and pinpointing the lesion, special light source was adopted in bronchoscopy by Lam et al in 1992 called auto fluorescence bronchoscopy. Bronchoscopy target became a little appropriate by CT scanning of the chest. Spiral CT scan furthur improves overall outcome of

## AN INTRODUCTION TO BRONCHOSCOPY

therapeutic bronchoscopy by allowing a view of extraluminal hilar and mediastinal structures as well as gives clarity about the position of endobronchial lesion, the length of stenosis and the site of stenosis and the site of tracheobronchial needle aspiration biopsy. The drawback of not getting the mucosal infiltration details of the lesions was overcome by Becker in 1999 by endobronchial ultrasound that provides details of images of multi-layers of bronchial wall as well as of the adjacent mediastinal structures upto 4cm distance. Bronchoscopy has attained one of the most commonly performed invasive procedures by leading pulmonologists. Tremendous performance and utilization has been observed especially in the last decade, particularly using video bronchoscopy and all kinds of interventional procedures both for diagnostic and therapeutic indications. Endobronchial ultrasound which whence introduced was put aside as expensive toy has now been accepted as wonderful diagnostic tool which is likely to replace mediastinal scopy as a preferred staging procedure for mediastinal lymph nodes in patients suffering from lung cancer. This also allows viewing cartilage involvement that is not detected by HRCT.

Presently, new optical and tactile sensors, using chip technology and neural structures (Robot technology) utilizing eye-trackers and brain- wave sensors is being used to improve the yield to maximum and decrease the patient discomfort to minimum.

Independently working true robots may be the future operators both in diagnostic and therapeutic bronchoscopy. Endoscopic capsule with remote control system will be functional in the future functional drive of this Endoscopic capsule shall be by energy derived by connecting to steering device by wire technology.

Similarly magnification device to view of penetrated (2-3 mm of tissue) can be obtained by endoscopic optical coherence tomography. Presently electro navigators are being utilized to guide down to the target lesion. Following localization and with better visual endoscopy which is achieved through 3D CT and endobronchial ultrasonography, the instrument can be taken to the target lesion, deep into the organ and therapeutic uses of radio-frequency waves or microwaves can be made. Pathological tissue can be destroyed in a limited portion using high intensity focused ultrasonography, MRI can be used for mediastinal structures.

Nano-technology and bioengineering are the future players to achieve perfect functional achievement and results. The performance shall be on a molecular basis, on self-organized micro machine that has the propensity to reorganize or replicate when required.

Application of biotechnology shall help replacing the damage mucosa or cartilage following bronchoscopy such post intubation stenosis, using fibroblast-mesh-implant to repair fistulae or implanting cultured bioprosthesis. The application of these newer technologies have to be enforced judiciously so that best health-care, patient-friendly and the least-hazardous effects are passed by intelligently using them by those who are trained with ethical perfection to adopt the newer technologies so as to deliver the goods successfully in Toto.

-----  
-----

## BRONCHOALVEOLAR LAVAGE

**Introduction:** Bronchoalveolar lavage (BAL) today is a useful and safe method of sampling cellular and biochemical components from the lung. BAL performance and BAL fluid processing has recently been standardized from technical angles, to improve diagnostic yield and diagnostic accuracy.

**Technique:** BAL technique involves introduction of sterile saline into lung through fiberoptic bronchoscope to obtain secretions, cells and proteins from the lower respiratory tract. This has been in use for many years in treating cystic fibrosis and severe asthma and to remove mucus plugging in patients not responding to other treatment. It remains the only effective treatment for alveolar proteinosis. Meticulous technique and expertise are essential for successful studies. In high risk hypoxemic patients non invasive positive pressure ventilation via a face mask can be used.

**Indications:** BAL can be used to confirm asbestos exposure, identification of reactivated tuberculosis and cytological diagnosis of tumors beyond the visual range of fiberoptic bronchoscope (FOB). Diagnosis of centrally situated lung tumour is easy with FOB, but diagnostic accuracy in peripheral lung lesions which is poor with FOB has improved with BAL. A success rate of 65% diagnosis has been obtained in an Indian study. BAL cellular analysis may help in identifying interstitial lung disease. The normal range of BAL cytology is provided in the table -1.

Raised lymphocytes in BAL fluid are found in sarcoidosis and extrinsic alveolitis. An increase in mast cells in sarcoidosis could represent initiation of fibrosis. Raised neutrophils, macrophages and eosinophils are found in cryptogenic fibrosing alveolitis. Similar changes are seen in collagen vascular disorders. However, mast cells in extrinsic alveolitis and lymphocytes in cryptogenic fibrosing alveolitis have also been reported. The alteration in cell count may provide a clue to activity of the disease in sarcoidosis and may guide the treatment in cryptogenic fibrosing alveolitis. The lymphocytosis seen in some early cases of idiopathic pulmonary fibrosis may represent a sub group which improves with steroids.

**TABLE - 1**  
**CELLULAR COMPONENTS OF BALFLUID IN**  
**NORMALS**

Total cell count	10-15x10 <sup>6</sup> /dl
Macrophages	84±1%
Lymphocytes	11±1%
T Cells	62±2%
Helper T (CD4)	46±3%
Suppressor T (CD8)	25±2%
B Cells	5±2%
Neutrophils	<.1%
Eosinophils	<.1%
Basophils	<.1%

It can be used to understand pathogenesis of diseases like drug hypersensitivity, emphysema, occupational diseases, adult respiratory distress syndrome and bronchial asthma. Carrying out

**AN INTRODUCTION TO BRONCHOSCOPY**

BAL in various stages of the disease/disorder could illustrate the varying cytological and biochemical responses found in these disorders with time. BAL technique has also been used with good tolerability in establishing diagnosis of pneumocystic carinii, cytomegalovirus legionella pneumonia, fungi and mycobacterial lung infections (Table II). However, sputum induction with nebulised saline may replace BAL in patients with HIV infection. BAL is a much preferred investigative tool over invasive procedures like transthoracic needle biopsy and exploratory thoracotomy. In asthma patients preoperative use of bronchodilator prevents postprocedural (BAL) fall in FEV & forced vital capacity which otherwise occursevenin mild asthma cases. Diagnostic value of BAL cytology is shown in table-III.

**TABLE - 2  
BALASADIAGNOSTIC TOOL**

<b>1. Infectious Diseases</b>
Pneumocystic carinii Legionella
Pneumonia Mycobacterium
tuberculosis Hemophilus
influenza Mycoplasma
pneumonia Histoplasma
capsulatum Toxoplasma gondi
Strongyloides stercoralis
Respiratory Syncytial Virus
Smear negative Tuberculosis
Pulmonary mucor mycosis
<b>2. Non-InfectiousDiseases</b>
Bronchial asthma
Alveolar Proteinosis
Histocytosis X

Pulmonary malignancies

**Possible helpful**

Pulmonary haemorrhages

Eosinophilic lung disease Asbestosis

Hypersensitivity pneumonitis

Idiopathic pulmonary fibrosis

Sarcoidosis

**TABLE-3  
DIAGNOSTIC VALUE OF CELLS IN BALTENID**

<b>A) Neutrophils</b>	a) 1-15% - fibrosingalveolitis - Cryptogenicfibrosingalveolitis - Asbestosis
	- Rheumatologicalabnormalities b) 50% - Infectiveetiology c) 50-90% - ARDS
<b>B) Eosinophils</b>	>20% - Pulmonaryeosinophilis
<b>C) Lymphocytes</b>	a) 15-40% - sarcoidosis - Tuberculosis - Berylliosis - HIVLungdisease - Druginducedlungdisease b) 50%eosinophilicAllergicalveolitis

**Adverse Effects:** Minor side effects after the procedure include fever, chills and transient alveolar opacities as seen radiologically. Fever is directly related to volume of BAL fluid used, release of proinflammatory cytokines from alveolar macrophages and rarely due to bacterial infection in 6.5% of cases. In asthma patients adverse effects of bronchoscopy & BAL include hypoxemia, bronchospasm, fever and crepts, wheeze or bleeding due to transient alveolar infiltration include recovery from the procedure, nosocomial. More serious complications infection (including mycobacteriosis) and pulmonary haemorrhage. The removal of tenacious mucus plugs in severe unremitting asthma and exacerbations of severe infection in cystic fibrosis may be life-saving but risks to the patient are high Nevertheless, whole lung lavage in silicosis and alveolar microlithiasis has not been a proven success. As of now, bronchoalveolar lavage remained an investigative technique and a research tool. It has attained the status of an important diagnostic tool over these years. Relative contraindications of BAL are shown in Table IV.

**TABLE: Relative Contraindications of BAL**

1. PaO<sub>2</sub> below < 70 mm Hg
2. Age > 65 years
3. Severe cardiac disease
4. FEV<sub>1</sub>> 1 litre
5. Extensive lung infiltration (>than 50%)
6. Prothrombin time less than 50%
7. Platelet count less than 50,000/mm<sup>3</sup>
8. Instable haemodynamic (Mean arterial pressure less than 60 mm Hg)

-----  
-----

**TRANSBRONCHIAL NEEDLE ASPIRATION  
(TBNA)**

**Introduction:** Transbronchial needle aspiration (TBNA) is mainly used as a diagnostic procedure to take samples from peri bronchial or sub-mucosal lesions using a needle attached to a catheter which is introduced through a rigid or flexible bronchoscope. It is safe, efficacious and cost effective method to diagnose and stage lung cancer as well as to diagnose granulomatous lesions such as sarcoidosis and tuberculous lymphadenitis. The method has not gained it's popularity with as much pace as it could have been since it's introduction six decades back; the higher cost and slower pace in imparting training might have played some role. More than 50% of TBN, As are performed in USA, the real cause of it's being underused more so in Asia lies in cost factor, under training, lack of experience, poor safety profile and concerns expressed about poor diagnostic yields.

Diagnostic indications: These are listed in the table I:

**TABLE -I  
(DIAGNOSTIC INDICATIONS OF TBNA)**

- A. 24-27
  1. Diagnosis and staging of lung cancer.
  2. Identifying inoperable cancers.
  3. Diagnosis of peripheral nodule & mass.

- B.** Relative indications included diffuse infiltrative lung disease, tumors, rejection of transplanted lung and severe illness that does not allow open lung biopsy

The sensitivity, specificity and accuracy of TBNA in lung cancer is variable from 60-90%, 98-100%, 60-90% respectively, depending upon technique, method, patient selection and mediastinal metastatic involvement. These indicators in comparison with granulomatous lung disorders are shown in table II.

**TABLE-II COMPARASION OF TBNAUTILITY**

Disorder	Sensitivity	Specificity	Accuracy
Lung Cancer	60-90%	98-100%	60-90%
Sarcoidosis	53-66%	100%	54-65%
Tuberculosis	45-83%	100%	50-85%

Diagnostic yield of TBNA can be as low as 0-20% in the hands of experienced bronchoscopists - with complication rate of 0.26%. It is always better to update theoretically, practise on lung models, review the CT scans before undertaking TBNA, and develop expertise with trained staff to work in a bronchoscopy suite. Important points during the procedure include placement of needle at an angle of 45 degree to the airways, ensured penetration of the needle upto the hub, supporting the TBNA catheter by channel of the scope, and stopping the aspiration before putting the needle into the airways. Two adequate specimen smears in alcohol and two samples along with all flush solution to be sent to cytopathologists. Following these guidelines has improved diagnostic yield from 21% to 48% and from 33% to 81%. Rapid

on site evaluation (ROSE) improves diagnostic accuracy and obviates the need for invasive & costly investigations. Abnormal yield of TBNA has been given in table III.

**TABLE III:  
ABNORMALYIELD OF TBNA**

---

<ol style="list-style-type: none"> <li>1. Bronchial or endobronchial tumours</li> <li>2. Infections                             <ul style="list-style-type: none"> <li>- Aspergillosis</li> <li>- Coccid mycosis</li> <li>- Actinomycosis</li> <li>- Tuberculosis</li> <li>- CMV</li> </ul> </li> </ol>	
<hr/>	
<ol style="list-style-type: none"> <li>3. Hypersensitivity pneumonitis</li> <li>4. Rheumatoid lung disease</li> <li>5. Vasculitis</li> <li>6. Alveolar proteinosis</li> <li>7. Granulomas-                             <ol style="list-style-type: none"> <li>a) Non necrotizing granulomatous inflamation</li> <li>b) Necrotizing granuloma</li> <li>c) Caseating grauloma</li> <li>d) Sarcoidosis</li> <li>e) Peribronchial granuloma</li> </ol> </li> </ol>	

---

To improve diagnostic yield by TBNA various adjuvant have been used as shown in Table IV.

**TABLE IV**  
**ADJUVANT METHODS TO TBNA**  
 (To improve diagnostic yield)

---

1. Fluoroscopy
2. CT/CT fluoroscopy
3. Virtual bronchoscopy
4. Tip position technology
5. Endo bronchial Ultra Sound (EBUS)
6. Positron Emission Tomography (PET)
7. Combined PET&CT
8. Electromagnetic navigation

---

Risks & complications of bronchoscopy have been listed in the table V.

**TABLE-V**  
**RISK & COMPLICATIONS**

---

**Major**

- Pneumothorax
- Haemorrhage
- Radiation exposure

**Minor**

- Cardiac arrhythmias
- Cardiac ischemia
- Hypoxemia

---

Sensitivity TBNA can be improved to 83- 87% by using spiral CT scanner (CT fluoroscopy) but it requires more time and thus excessive unnecessary radiation exposure occurs both to the patient as well as assisting staff. Virtual bronchoscopy using spiral CT for TBNA has been used with success but does not provide final needle placement to the point. 3-D CT data has been used in real-time bronchoscopy tip position technology for TBNA, especially in non-visible extra-bronchial lesions.

Ultrasound used endobronchially has increased the yield of conventional TBNA from 58% to 76-86% in mediastinal lymph node lesions. The endobronchial ultrasound guided

**In case of general anaesthesia**

- Nausea / vomiting
- Sore throat
- Muscle pains
- Difficult breathing
- Bradycardia
- Altered blood pressure
- Kidney damage
- Choking (if water is ingested by mistake before anaesthesia, effect wears it).

Local anaesthesia is sprayed topically before flexible bronchoscopy is done. This will initiate coughing but this will settle as the anaesthesia begins to work. A feeling of thickness conveys sufficient numbness. If there is cough during the procedure, it means more anaesthesia is required. Premedication

## AN INTRODUCTION TO BRONCHOSCOPY

with a sedative does help in allowing relaxation during the procedure.

Conventional fluoroscopy being used to guide TBNA in peripheral pulmonary lesions of more than 2 cm diameter. CT is used to pinpoint puncture site with a sensitivity of not more than 57% and specificity of not more than 74% as it has limitations in lesions which lack good contrast with surrounding tissues. Tran's bronchial yield of 85% and Tran's esophageal yield of 78%, if combined, provide results, comparable to mediastinoscopy results of 94% in mediastinal staging of lung cancer. Similarly, a diagnostic yield of 82% by EBUS guided TBNA has been recorded in stage I & II sarcoidosis.

A metabolic imaging technique based on biological activity of neoplastic cell, thus using tissue function rather than its anatomy is positron emission tomography (PET), where PET camera identifies the neoplastic or inflammatory cells having increased cellular uptake of glucose and higher rate of glycolysis. PET serves as a guide to TBNA in evaluating lymphadenopathy in lung cancer as it has higher accuracy and sensitivity than TBNA alone (88% compared to 67%) in differentiating benign and malignant mediastinal lymphadenopathy. Combined EBUS in PET gives 94% accuracy in mediastinal lesions with TBNA. Integrated PET and CT can also provide successful results.

Electromagnetic navigator using virtual bronchoscopy and 3-D-CT images in combination with a steerable probe, peripheral lung lesions can be successfully sampled (69-88%) by TBNA along with transbronchial lung biopsy, brushing and curettage. Initiated by Shieppati in 1949 as rigid TBNA, and performed over flexible

bronchoscope in 1983 by Wang and Terry, present time TBNA-an invasive bronchoscopic technique, needs to be more utilized as a routine bronchoscopic procedure. Young bronchoscopists need to develop skill & expertise and strictly, following guidelines. Cutting down the cost of the needle for TBNA, shall improve the diagnostic yield as well as optimally utilize this presently being under used technique, especially in the developing countries like India. This would broaden the spectrum of diagnostic bronchoscopy as well as bring forth newer diagnostic yield in respiratory medicine.

-----  
-----



**BRONCHOSCOPIC LUNG BIOPSY FOR DIAGNOSING MILIARY TUBERCULOSIS CAN IT BE FIRST LINE INVESTIGATION?**

Bronchoscopic lung biopsy is a safe and effective method of diagnosing miliary tuberculosis. Granulomatous inflammation can be demonstrated in majority of patients and identification of Acid fast beclli in these specimens need to be a pre-requisite for making a positive diagnosis of miliary tuberculosis. Nevertheless, bronchoscopic yield does not confirm the diagnosis of tuberculosis in the absence of acid fast bacilli. And if it is non caseating granulomatous histologic finding of the transbronchial aspiration, a long list of diagnoses has to be considered in the differential Necrolizing gramloma with negative staining for AFB are often encountered in sarocoidosis. Transbronchial lung biopsy is safe only in safer hands and should be done only when diagnostic difficulties arise from other investigations being inconclusive. Since granulomatous inflammation with caseation cannot be demonstrated in more than 1/3rd of cases even after histologic examination of transbronichial yield & were put on empirical treatment, therapeutic trial with antikoch's treatment in suspected cases of miliary tuberculosis shall amount to same, without subjecting the patients to unnecessary, complications of bronchoscopy which occur in/with most of the bronchoscopy suites and are not frequently recorded or reported. Bronchoscopy, thus, should not be recommended as a routine investigation for miliary tuberculosis diagnosis through transbronchial biopsy, and shall remain the first line diagnostic procedure for diagnosing and

staging malignancy, diagnosing and treating haemorrhage and diagnosing atypical sarcoidosis and interstitial lung diseases.

Bronchoscopy in tuberculosis shall be routinely indicated in cases of endobronchial TB (when plain chest X-ray may not demonstrate), in the absence of parenchymal lesion, smear negative cases and tubercular lymphadenitis.

The exact role and cost effectiveness of transbronchial needle aspiration has to be evaluated with comparative trials, before this interventional procedure is promoted as a routine procedure for its optimal utility. Experience and training has to be imparted before results, in the form of performance and yield are improved and evaluated.

-----  
-----

## THERAPEUTIC BRONCHOSCOPY

Bronchoscopy is an important diagnostic as well as therapeutic tool in managing certain inflammatory, infectious and malignant disorders of the respiratory system. Nearly half of the bronchoscopies account for therapeutic procedures. Nearly 50-75% of bronchoscopies are done to remove retained secretion, 12% for haemoptysis and less than 0.5% for foreign body removal and assisting endotracheal intubations. Frequently, diagnostic and therapeutic bronchoscopies are performed simultaneously. Other therapeutic indications include;

- 1) Removal of mucus plug which is not being cleared by other non invasive techniques.
- 2) Dilation of stricture or stenosis.
- 3) Debulking of endotracheal abnormal tissue to maintain airways lumen.
- 4) Draining an abscess or cyst.
- 5) For procedures such as brachytherapy, cryotherapy, electrocautry etc.

**Haemoptysis:** Bleeding can be stopped by endobronchial tamponade, fibrin precursor application, iced saline and epinephrine. If bleeding is >200mlper 24 hours, rigid bronchoscopy is preferred to avoid dangerous & fatal complications such as asphyxiation, as rigid bronchoscope can

provide both laser suction device as well as balloon-tipped catheter to tamponade the bleed.

**Foreign body removal:** Rigid bronchoscope is ideal for the extraction of tracheobronchial foreign body, especially in children and incase the foreign body is larger one. Flexible bronchoscope with newer ancillary equipments such as wire basket, biopsy forceps and retrieval forceps to grasp and remove larger foreign bodies in the proximal airways are being successfully used. What is most important is to remove the foreign body along with the flexible bronchoscope, keeping the foreign body in the middle of the scope and keeping an eye on the foreign body, so that it is not lost while being extracted.

**Tracheobronchial stents:** Endobronchial stents are used when there is airway obstruction, often caused by malignant lesions. They help, not only in relieving the obstruction of airways, but also prevent respiratory failure. Stents of different shapes & sizes are more useful in diseases affecting trachea or bronchi rather than airway disease involving lobar or distal bronchi. Silicone stents are better suited for benign & malignant lesions of airways, whereas covered metallic stents are useful in malignant airways stenosis. Silicone stents are essentially placed, manipulated & removed by using rigid bronchoscope, metallic stents can be inserted by flexible bronchoscope or fluoroscopic guidance. Complications with silicone stents include migration of stent and inspissations of thick mucous within stent-lumen. Metallic stents seem providing growth of granulation tissue that hinders in it's removal & replacement. Uncovered metallic stents should never be inserted in an airway with malignant lesion because cancerous

## AN INTRODUCTION TO BRONCHOSCOPY

growth through wire mesh negates the benefit of placement of stent.

**Dilatation of airway stenosis:** Rigid bronchoscope when repeatedly passed using gradually increasing diameter bronchoscopes, help in dilatation of trachea and main stem bronchus. Shorter stenosis can be dilated with balloon dilation through flexible or rigid bronchoscopes. The procedure is effective in stenosis of intrinsic origin rather than of extrinsic nature; and has to be repeatedly done in most of the patients having chronic benign strictures. Short length membranous or web-like lesions involving short length of airways are effectively dilated. Surgery or stent therapy is essential for transmural strictures and long-segment strictures of airways.

**Laser therapy:** It is performed using Nd- Y AG laser, both for benign & malignant tumours, to relieve symptoms of airway obstruction, rather than curing the neoplasm. Results are more than 90%; results are obtained quickly with rigid rather than flexible bronchoscope. Complication includes haemorrhage, pneumothorax & pneumomediastinum. The cost of equipment and need for specialized training to perform with laser are major hurdles. Laser therapy is not useful in peripheral airway even visible lesion except when there is a post obstructive pneumonia when patient cannot undergo surgical resection.

**Brachtherapy:** Bronchoscopic delivery of radiation from within the airway lumen to relieve airway obstruction caused by malignant tumour, is brachytherapy. This is attempted as palliative treatment in those who had full dose external beam radiation. Response is good in nearly 60% of patients, lasting for few weeks

or months. Complications are seen in 6-8% of cases, mostly fistulae formation between airways & other thoracic structures. In high dose radiation patients, serious hemorrhages, causing massive haemoptysis may occur.

**Phototherapy:** Intravenous administration of haemato- porphyrin derivative followed by putting on light on the airway malignant tumour through bronchoscope for several minutes at an appropriate wavelength, results in production of toxic oxygen radicals as a result of chemical reaction when haemotoporphyrin derivatives fluoresce. Complete response is seen in nearly half of the patients, sustained for at least one year. Sunburn on skin affected by bright light, haemoptysis and thick necrotic expectoration are the commonly encountered complications. Further therapeutic bronchoscopy may be required to clear this pseudomembrane of thick necrotic material.

**Electrocautry:** Alternating electrical current is bronchoscopically delivered to coagulate and vaporize endobronchial lesions, using Argon plasma coagulator, both with rigid or flexible bronchoscope. 55-75% of patients get symptomatic relief of airway obstruction. Instrument & electrocautry probes are not costlier and thus it is a good alternative to expensive laser therapy. Endobronchial fires, electric shock to the patient or the operator are the complications which can occur.

**Cryotherapy:** Repeated cycles of cold application followed by thawing, using liquid nitrogen or nitrous oxide to achieve -80 degree Celsius temperature, applied through cryophobes via rigid or flexible broncoscope, helps in causing cold- induced death of malignant cells. This can be applied to treat smaller polypoid

lesions, visible in the distal airway. Cryotherapy is not costly and subjective relief of airways obstruction is achieved in more than 3/4th of the cases where it is used for benign as well as malignant lesions. Complications are few and rare, but therapy requires longer duration and repeated freeze-thaw cycle. Repeated bronchoscopy thus, is not preferred by most of the patients.

**Bronchoscopic resection of airway lesion:** Rigid bronchoscopy is preferred for bronchoscopic resection of large neoplastic growths of trachea or mainstem bronchus to provide palliative therapy for immediate relief of airways obstruction. Severe bleeding is the major complication, often controlled by tamponading the bleeding points by the rigid bronchoscope itself.


-----  
-----

## GUIDELINE FOR BRONCHOSCOPY

Guidelines form a concrete basic of interventional pulmonary procedures and strictly following the guidelines by an expert group of pulmonologist is always rewarding, especially in case bronchoscopic procedure is being carried out. A large number of specialists are being attracted towards subspecialties in super speciality of respiratory medicine in the recent decade. The adventure, the skill, the outcome and the professional satisfaction are the main reasons. The no. of performing more than 5 lacks of bronchoscopies per year has fastly increased in the last few years with more than 15,000 airways stents being placed every year worldwide. So, is the performance of complex bronchoscopic procedures, leaving apart the management of haemobysis which is being routinely done in OPD bronchoscopy suite. However, there is lack in uniformity in training and offering of hands-on skill being transfered, especially in procedures like transbronchial needle aspiration and placement of stents.

Since inherent risks with these procedures may effect patient safety, importance has be given to lay down guidelines regarding type of equipment, personnel required, risks involved and training required for each procedure, indications and uniform training practice in different fellowship programmes. The capability of bronchoscopist achieves the best results if a trained, competent and dedicated staff is assisting. Hence, preparation and training of such assisting personnel is of utmost importance to expliot best potential with minimum complications in each individual procedure.

The training of bronchoscopists to achieve competence may involve virtual reality-stimulated bronchoscopy. "Do one, but do best", should be the new motto for those learning the new procedure, thus putting aside the old one, "See one, do one, teach one," which is no longer accepted. This is what American College of Chest Physicians guidelines offer.



## **RIGID BRONCHOSCOPY**

This is an invasive procedure, requiring general anaesthesia and is done in a bronchoscopy operation room. FOB may be combined with rigid bronchoscopy to have better distal airway visibility and suctioning. The scope a halogenated light, and accompanying instruments such as graspers, forceps, suction device, syringes & tubing's and saline solution and jelly for lubrication form the basic equipment.

Procedure is done under general anaesthesia with adequate sedation and muscle relaxations, dedicated operator with trained staff are all in action as a team for patient safety and fruitful yield.

Patient is in supine position. Rigid bronchoscope is introduced; epiglottis is gently lifted to view larynx & vocal cords. Then scope is turned 90 vertically in order to pass through cords and on reaching trachea, the scope is turned back to its original neutral position. Before bronchoscope is gently advanced towards carina and systemic insertion into each bronchus ventilation is started via side port. Telescopes are entered through bronchoscopy. Mechanical tumour ablation and tracheo-bronchial laser therapy may also require rigid bronchoscopy.

In the presence of tracheal obstruction, extreme requirement of oxygen and ventilatory support and coagulopathy, rigid bronchoscopy is relatively contraindicated. Caution must be

## AN INTRODUCTION TO BRONCHOSCOPY

exercised in preventing any injury to gums or teeth, creating any tracheo-bronchial tear or causing severe haemorrhage, which are usually less than 0.1%. 20 procedures in a supervised setup provide basic competency and has to perform more than 10 procedures per year to maintain competency by a dedicated operator.

ST changes, arrhythmia, hypertension and increase in heart rate are common events developing in patients undergoing rigid bronchoscopy. These changes are more in those having comorbidities. Routine use of conventional monitoring like ECG may not offer to record these adverse cardiac events, as compared to holter monitoring. However, 5 lead ECG may offer a good alternative in peri-procedural period if holter monitoring is not possible. Rigid bronchoscope and angled 30° & 90° scopes to look. Stimulation of upper respiratory tract during intubation and particularly the right upper tube orifice. Head is usually turned to right to enter into left mainstream bronchus and to the left to enter into the right bronchus. The completion of preliminary examination is followed by the procedure to be addressed for which bronchoscopy has to be done, is, dilation, foreign body extraction, stent placement, laser ablation etc. A flexible bronchoscope can also be inserted through right bronchoscope in case more detailed examination or washings or laser/photodynamic ablation are required to be performed.

Important indications of rigid bronchoscopy include foreign body extraction, bleeding, tracheal or bronchial strictures dilation, deeper biopsy specimen (if inadequate by FOB), and relief of airway obstruction, stent placement and pediatric, laryngoscopy initiate sympathoadrenal response resulting in haemodynamic

effects such as tachycardia, raised blood pressure, ST changes and cardiac arrhythmias. Rigid bronchoscopy results in subsequent haemodynamic effects but of greater magnitude and of longer duration.

ST changes occurring during rigid bronchoscopy be detected by holter monitoring and may range from 10-18% as compared to 73%, utilizing routine anesthesia monitoring system. Whereas, preoperatively, ST changes can be detected varying from 38%, 90%, 96% and 100% using single lead, two leads, three leads, and five leads respectively.

Conventional monitor can detect 34% of all types of arrhythmias as compared to 80% of arrhythmia detected by holter monitoring. 12% out of 80% of these arrhythmias were associated with haemodynamic change. Holter monitoring can also detect supraventricular arrhythmias, mostly associated with hypertension in post procedural period.

Rigid bronchoscopy of lower respiratory tract often results in tachycardia, hypertension and hypoxaemia, which may not influence consequent adverse effects in patients with normal cardiovascular physiology but may result in significant adverse events in patients with coronary artery disease or respiratory disorder. Perioperative and post procedural adverse events such as ST changes and arrhythmias are more common in the elderly patients and those with comorbidities. Intensive monitoring is required up to 4 hours in post procedural period, since arrhythmias are most common to occur during that period.

## AN INTRODUCTION TO BRONCHOSCOPY

Other complications of rigid bronchoscopy may include hypotension, bradycardia, bronchospasm, post operative stridor and ventricular bigeminy.

Bradycardia may be treated with atropine 0.6 mg/kg. Hypertension & tachycardia may require propofol 40 mg bolus or esmolol bolus 100mg. Injection ephedrine may be required for hypotension and injection lignocaine 1 mg/kg, for ventricular premature beats.

-----  
-----

## FLEXIBLE BRONCHOSCOPY (FOB)

Flexible bronchoscopy is a minimal invasive procedure to visualize nasopharynx, larynx, vocal cords and tracheo- bronchial tree, being utilized both for diagnostic and treatment of bronchopulmonary disorders.

It requires a bronchoscopy suite, a fiberoptic bronchoscope (FOB), a light source, biopsy forceps, cytology brushes, needle aspiration catheters, supplemental oxygen, suction apparatus, sphygmomanometer, pulse oximetry, c-arm fluoroscope, and an endotracheal tube with resuscitation equipment. Fluoroscopy may be useful in transbronchial biopsy while a video monitor is an additional accessory.

Patient safety and fruitful yield in every procedure is directly related to the capability of bronchoscopist along with his competent, dedicated, trained staff of bronchoscopy suite. The procedure is done under local anaesthesia, with or without conscious sedation. 4 hours fasting before the procedure is preferable. In a supine or semi recumbent position, local anaesthesia is applied at orifice of entry (nose), nasal passages and pharynx. With a bite block in place, FOB is introduced with an oropharyngeal examination. Reaching the vocal cords, reanaesthetize topically, examine the cords for adduction or abduction, pass through the vocal cords and go ahead for airway inspections. Diagnostic and therapeutic procedures through FOB are shown in table.

<b>TABLE USE OF FOB</b>	
<b>Dianostic</b>	<b>Therapeutic</b>
BAL	Balloon dilatation
Endo/ Transbronhial laser biopsies	Endobronchial ablation
Cytologic wash/ brush	Electrocautery
TBNA	Photodynamic therapy
EBUS	Brachyt herapy
Auto fluorescence bronchoscopy	Selective stent placement

Flexible bronchoscopy can also be indicated in cases of lung mass, undiagnosed pulmonary infiltrates, mediastinal lymphadenopathy, lesions & airways disorders. Flexible bronchoscopy may be relatively contraindicated in relation to respiratory and bleeding status. Unstable patients or those requiring prolonged procedures, rigid bronchoscopy may be preferred.

FOB is low risk procedure in competent hands. However, common complications of morbid value are encountered in less than 1% of patients in the form of bleeding, cardiopulmonary arrest, cardio arrhythmias, pneumothorax and respiratory depression. Mortality rate is 0.04%.

Bronchoscopy should provide diagnostic/ therapeutic yields without inducing major complications. A trained bronchoscopist is certified only if he completes 100 procedures in a supervised setting to exert his basic competency. This has to be maintained by

performing more than 25 procedures per year, which must be receiving counter signatures from chief of bronchoscopy unit. And this competency must excel in assisting a dedicated operator in the performance of the procedure before he is declared an efficient student in bronchoscopy. (Student-as he is to learn more and more innovative approaches.)

#### **UTILITY OF ENDOBRONCHIAL BLOCKER TUBE**

Endobronchial blocker tube is a useful instrument having significant place in surgery & anesthesiology. It has a pilot balloon to allow the attending anaesthetist to digitally monitor varying degree of cuff inflation.

Flexible fibroptic bronchoscope can be inserted through bronchoscopic port. The optional shape of the blocker tube allows appropriate angle between the bronchial tube and the bronchoscope for excellent maneuverability. The port is also equipped with packaging material and a lid for using with the bronchoscope, to permit an airtight operability of the bronchoscope whether being in use or not. Similarly, the packaging material permits airtight up & down movement of blocker tube as well.

A standard 15 OD connection to connect either the respiratory circuit or the anaesthesia circuit is also provided.

Trocheal tube connector allows connecting various trachial tubes as well as flexible tubes, in addition to laryngeal masks and tracheostomy tubes. Endobronchial blocking tube is firmly



## AN INTRODUCTION TO BRONCHOSCOPY

connected to joint connector with the help of intra blocking tube clamp, to minimize operative displacement of tube.

Potential trauma to bronchial wall has been reduced to minimal by especially designed cuff using low pressured barrel shaped balloon to keep intimate contact with the end bronchial wall. Suction port allows degeration aspiration of secretions, and administration of oxygen to collapsed lungs.

-----  
-----

## **PERFORM ONE, PERFORM BEAUTIFUL DIAGNOSTIC-YEILDING AND PATIENT FRIENDLY BRONCHOSCOPY**

Bronchoscopy is done either for diagnostic yield or for therapeutic benefit to the patient. The procedure for every time you perform is a challenge in itself. The bronchoscopist when performs, the result oriented performance should never confine to a time bound procedure. It should always be linked to perfection and using every possible device to achieve the target, leaving no possibility for asking an excuse for repeat bronchoscopy. Because no yield and demand to repeat shall bring forth a situation of tremendous disliking response by the patient for the harrowing experience he had passed through with no results in hand. This will be distressing to the bronchoscopist as well.

A three experience, as it is known as, bronchoscopy requires stress checking of, if it is really needed, it shall serve the purpose of diagnosing or serving therapeutic tool; and incase a scene of non-diagnostic yield is ever coming on to an interventional pulmonologist, it is better not to perform the bronchoscopy. Since it is challenging procedure for the bronchoscopist, he must confirm the target and practice how to hit the target cent percent in the pre operative theater, screening thoroughly by a battalion of investigations and practicing multiple manipulations on lung model before the actual procedure is performed and should always be equipped to efficiently use all the armamentarium such as needle aspiration and biopsy. At the same time, it is a procedure that poses quite some discomfort to the patient; but the performance-excellence should never compromise with patient discomfort during bronchoscopy procedure. No doubt, people

## AN INTRODUCTION TO BRONCHOSCOPY

have emphasized patient comfort, and patient friendly technology usage, but the demand to keep a place for repeat-procedure should because favouring for comfort if bringsforth non-yeilding diagnostic bronchoscopy shall ultimately be non-satisfying to both patient and professional (bronchoscopist). And in such a situation, a request for repeat bronchoscopy shall bring forth total dissatisfaction toward the pulmonologist. People have shown good effect of music in creating patient friendly atmosphere in the bronchoscopic suit. Similarly good outcome of patient satisfaction after bronchoscopy has been found in patient- centered bronchoscopy centres. But we prefer a step further. We must target to ensure diagnosis-yielding bronchoscopy and that too, in an atmosphere conducive to patient comfort. More stress needs to be laid down on imparting training to make an adept rather than carving out a routine bronchoscopist, and he is trained to work on every case as a prudent, skilled bronchoscopist to yield the best and complicate the minimum and always concentrate on achieving the target of the procedure, and at the end of successful performance, he must say, he is still learning. His goal must be a successful bronchoscopy both diagnostic and therapeutic, and satisfaction of his patients should empower his propensity. He must create an atmosphere of a competent staff around to assist him. These trained personal (if needed) should always understand the bronchoscopist to have skillful performance with proper rotation of bronchoscope as and when needed, along with keeping a watch on complications. The unintentional complications such as heamorrhage or pneumothorax that might occur despite all precautions and competent careful performance may not irritate the patient but the agony of repeat bronchoscopy against a non-yielding previous bronchoscopy is difficult to tolerate. Let us concentrate on uneventful, successful, total goods delivering

performance in an atmosphere of near total comfort to the patient, where lurch for the other three pigeons in the sky is forgotten, and the beautiful one is possession should be felt enough to inspire to catch another one beautifully. It remind me a live discussion that out of 2000 earlier performed bronchoscopies in India, the result oriented or good yield producing and without major complication were only 200; only 20 bronchoscopies were performed with minor complications and the perfectly conducted were only two contrary to this, the American counterpart revealed that 10 out of first 15 bronchoscopies were complicated but the rest of hundreds of bronchoscopies that followed were yield-rich, patient tiredly and without any major complications. That spirit must be imbibed major by teachers- trainers and should be allowed to be diluted by those selling bronchoscopes empowering with crash course, without any hands- on procedure under retro vision.

-----  
-----

**BRONCHOSCOPIC REMOVAL  
OF FOREIGN BODY (FB) IN AIRWAYS:  
PROCEDURE AND PRECAUTIONS**

Technique of bronchoscopically removing an airway foreign body (FB) is a state of art, best conducted successfully by an adept bronchoscopist, who has an excellent support of experienced and a trained team around. For excellent results, selection of the patient for appropriate indication is utmost important that yields successful outcome with minimum complications. The procedure to success depends on the preparation of the patient for the procedure, the assistance of trained technician to insert and manipulate the grasping instruments, with the bronchoscopist's primary concern to maneuver the bronchoscope to the target position to achieve. Even the expertise bronchoscopist must have a multiple practice sessions in the lung model prior to actual performance so as to realize using the appropriate instrument if and when required, depending upon the radiology film, and identifying, the desired position. Thus, all the baskets and grasping instruments are needed to be actually tested before putting to use in a bronchoscopic procedure. The infrastructure and the assisting team are assigned specific work for each member for the uneventful procedure. A team member looks after sedation and monitors the vital signs, while a bronchoscopic assistant who is adept in removal of instrument, helps the bronchoscopist in doing so during the procedure. The backup support of anesthesiologist and thoracic surgeon should always be ready to meet any untoward complications faced unexpectedly. The running time is not always short in case of non-asphyxiating foreign body in an adult but cring time and commitment of the attending bronchoscopist is always rewarding presence of erythema,

oedema, infection and granulation are always faced as long as FB remains in the airway; usually in inflammatory reaction develops within 24 hours of FB aspiration in most of the cases. And if acute respiratory distress is not warranting, a well planned procedure can be undertaken, where rushing for the procedure has no value and replaced with commitment to remove the FB, after properly studying the place, shape, size and structure of FB, in relation to the surrounding areas before a successful attempt is made. Radiological view morbidity and mortality presence of bleeding and granulation tissue often adds to the agony and many workers do use a short course of corticosteroids before removing the FB.

Rigid bronchoscope used to be the choice procedure in removing the foreign body in children now; flexible bronchoscope is being safely and successfully used for extracting foreign body in children. Removal of adult airway foreign body requires both skill and experience, so as to minimise the complication. Success rate also depend on the skill and expertise of bronchoscopist rather than the type of bronchoscope used, rigid or flexible. Successful performance of bronchoscopist must allow to transfer know how ability and prowess to the younger paleontologists to the true spirit of pulmonary medicine, keeping high standards in the procedure and safety of the patient while imparting knowledge. The actual technique involved in removing FB by using flexible bronchoscopy, which has advantage over rigid one, being operational with local anaesthesia, where patient remains under conscious sedation, which permits preservation of cough reflex that actually itself assists in FB removal. However, airway is not secured during the flexible fibreoptic bronchoscopic procedure. But experience has shown that patient can tolerate bronchoscope under conscious sedation and may not necessarily require

## AN INTRODUCTION TO BRONCHOSCOPY

complete sedation and control over ventilation. In a rare instance, if respiratory distress occurs, easy securing of airway can be achieved by placing an end tracheal tube, through which foreign body can be extracted. In case deeper sedation is required, laryngeal mask airway can be used for reasonable airway control during flexible bronchoscopy.

Most important precaution in removing foreign body from airway is not to push it distally to the airways "Fogarty Ballon" is quite useful to dislodge the FB and to help in bringing it proximally into the trachea before actually attempting its removal. Balloon then inflated helps in pulling the FB from the bronchial sub segment to trachea. Once in trachea, use of basket or forceps helps in removing the FB. For a small, soft, simple and friable. FB, some workers have encouraged the patient to sit and cough up once the FB comes in upper trachea and hence appreciated a highly successful yield. Regarding removal of foreign body from airway let this be made clearer that FB is never removed through working channel of bronchoscope. Once the FB is adequately captured by basket or forceps, and then the three (bronchoscope, grasping instrument and FB) are removed simultaneously with a constant eye on a FB, which is always kept in the centre of the airway. Always remove FB using oral approach of bronchoscopy, as there is always a chance of losing the FB in the nasal passages. In case of endotracheal intubation, the endotracheal tubes have to be withdrawn in conjunction with the bronchoscope with secured FB, followed by reintubation promptly. Foreign body extraction using optical versus non-optical forceps offers no added advantage.

Haemoptysis is a rare complication during FB removal from the airways and admittedly can be better controlled with a rigid

bronchoscope. But the fear of massive bleeding from the airways should not be the reason to prefer use of rigid to flexible bronchoscope in removing FB from airways. Removal of a sharp FB is a definite challenge that requires special skill, art and patience. The art lies in locating the sharp edge of the FB, and it is the freed sharp end that is grabbed and then FB is removed. Holding the FB from other end will expectedly complicate, as the sharp end is likely to be caught in the mucosa.

In case of larger FB or tissue impacted FB, laser may be used to break the FB or vaporize the granulation tissue, as is the case.

This is followed by the same procedure with similar precautions following all the set guidelines, and this actually holds the key to successful removal of FB from the airways without or with minimum complications. Despite variable and nonspecific presentation of FB aspiration, the radiographic evaluation is often useful in clinching in diagnosis. Therapeutic flexible bronchoscopy has become the gold standard in recognizing and localising the foreign body in the airways. Safe and successful removal of an airway FB through bronchoscope under local anaesthesia in recent years has seen pulmonary medicine excelling in the present era of medicine. Advanced bronchoscopy with aided improved imaging technology has helped in decreasing morbidity and mortality from non- asphyxiating FBs in the airways, through incidence of FB aspiration has not decreased. Deaths rates have been stable for the last five years; incidence of deaths due to bronchotracheal FBs had been 1.2 per 100,000 in USA in 1998. A decline in FB aspiration episode after 5th year of age may find an ascendance again in the 4th decade of life; and most of these asphyxiating events occur at home (41%), in

## AN INTRODUCTION TO BRONCHOSCOPY

restaurants (29%) and in a nursing homes or mental hospitals (14%).

Non-asphyxiating events are, however, seen in children, 75-95% of events occur in children under 15 years of age. In adults, it is after 6th decade of life, that such an event is observed, and that too possibly due to factors such as alcohol intoxication, sedative drugs, loose dentition, senility, mental retardation, Parkinson's disease, seizure, trauma or under the effect of general anaesthesia.

Classical triad of cough, wheezing and choking is present only in few number of patients following FB aspiration. If a large asphyxiating object occludes larynx, an acute attack of cough, hoarseness, choking and gagging is observed. Sometimes, even the patient is unable to speak and cyanosis develops. Heimlich maneuver is recommended for expulsion of FB. But if the foreign body is aspirated beneath the cords into subglottic or tracheal area, bouts of cough with inspiratory stridor is noted. FB is passes into either of bronchus, minimal symptoms or unilateral or localized wheezing may be the only finding. 10-20% in laryngotracheal, 30-40% in left bronchus and 40-70% in right bronchus, FB aspiration in airway is reported. Unlike children, FB aspiration in adults in mostly non-asphyxiating. Site of impaction often determines the clinical symptomatology, which can be symptom free (1%) or with symptoms such as wheeze (1%), choking (3%), chest pain (4%), breathlessness (16%), fever (21%) or cough (81%). Non-specificity in symptoms often lead to misdiagnosis, and diagnosis is made even after 1-2 decades of FB aspiration. In that situation, recurrent pneumonia, obstructive emphysema, bronchial stenosis, bronchiectasis, pneumothorax or pneumome- diastinum, bronchopleural fistulae, chronic lung disease, recurrent

haemoptysis, pleural effusion or empyema and even osteomyelitis of rib are faced as delayed complications of FB aspiration. Variety of FBs can be aspirated. These may be organic or inorganic substance. Dental crown, pins or coins are commonly seen. Endotracheal appliances, endotracheal tube segment or dental prosthesis and drugs (pills) are commonly seen in adults. Even hypodermic needles have been reported in drug addicts. Corns, seeds, beans and chicken or fish bone is commonly seen in adults as compared to children where nuts, seeds and pen appliances are mostly aspirated. As discussed various objects with varying shapes and structure pose every time a new challenge to bronchologist who has to individualize his approach each time, depending upon the type of FB, peripheral tissue reaction and area of impaction of FB in the airways.

Chest radiogram offers in radio-opaque FBs. Other radiological signs such as air trapping, atelectrasis, pulmonary infiltrates and shift of mediastinum do pointer towards FB aspiration. CT Scan, ultrasound scan and fluoroscopy also help in certain cases. In the present times, flexible bronchoscopy remains the gold standard in identifying and localizing FB in the airway. Gustav Killan in 1897 was the first o remove FB, using rigid bronchoscope. The success rate increased gradually over a period of more than ½ a century to the tune of 99% and with the complication rate getting reduced to only 0.2% and the fatality rate being less than 0.1%. Flexible bronchoscopy by Shigeto Ikkeda in 1968 revolutionized care of pulmonary patients. Doubts were raised at the initial stage over its safety but with expertise and advancement, flexible bronchoscopy has only achieved a performance status of almost 99% in USA in the present times, where it was initiated only as a diagnostic tool, but has become an accepted procedure therapeutic procedure,

giving 86-100% results in removing airway FBs. Multiple accessories have been devised to can be applied to use with the flexible bronchoscope such as grasping forceps. Balloon catheters, dormia baskets, Fish-net basket, multipronged snars, magnet extractor, cryoprobe and Neodymium-Yttrium- almunium-garnet (Nd Yag Iaser). The bronchoscopic removal of airway FB is a state of art that requires to observe all the necessary precautions and to follow the step-by-step guidelines to achieve higher success and minimize rate of complications. This three handed procedure requires trained assistants and associates to achieve the best and that can only be achieved, when the bronchoscopist pre-plans his operation and performs patiently while keeping his eagle eye on the target till last. In case of failure, surgical extraction may be sought, since management of foreign body is teamwork of pulmonologist, thoracic surgeon and anaesthetist, who always complement each other. It should never be taken lightly, as hypoxia may result and ultimately may prove fatal.

-----  
-----

## AIRWAYS STENTING

Airway stents are devices being placed at appropriate place to maintain tubular structure open stable in transcheobronchial free either by rigid or flexible bronchoscope. Fluoroscopic capability may be required for airway stenting. Procedure is done under local anaesthesia. The airway obstruction has to be reestablished for an appropriate lumen for insertion & placement of a stent. The choice adn size of stent depends on the experience of dedicated operator and different reviews CT images. The length of stent must be more than the length of the lesion, the diameter should be optional, since under-size will slip & over-size will over stress the airway well. These are best used in endorochial obstruction due to tumour, or extra bronchial airway compression due to tumours or other structures. These can also be used in tracheobronchomalacia & in sealing airway fistula.

Stents have to be avoided if nonviable lung is present beyond the obstruction. Removable stents are considered in case of benign disorders.

Complications may occur due to migration of stents and secondary infection. Even pain, haemoptysis, granuloma formation, breaking of stent and airway obstruction due to impaction or granuloma may occur.

Acquiring stent placement skill, basic competency needs to perform 20 procedures in a supervised setting, followed by 10 procedures by a dedicated operator for maintenance of competency which is essential.

-----  
-----

## **THE THERAPEUTIC BRONCHOSCOPY- EXPANDING SCOPE: CURRENT STATUS**

Interventional bronchoscopy both for diagnostic and treatment, after the introduction of flexible bronchoscope by Shigetomo Ikeda in 1968 has revolutioned the practice of pulmonary medicine, as is evidenced that 99% of bronchoscopists in USA are working with FB against 4% of experiences with rigid bronchoscopes. However rigid bronchoscope remains the procedure of choice in paediatric bronchology as well as in patients with massive haemoptysis, silicone stent placement, large foreign body removal and for better control of compromised airway. Major indications for therapeutic bronchoscopy include its use in intensive care units, giving urgent relief of airway stenosis due to benign and malignant tumors, removal of foreign body and in controlling haemoptysis. It may help and malignant tumors, removal of foreign body and in controlling haemoptysis. It may help in avoiding mechanical ventilation in-patients with respiratory distress, facilitate screening and permit time to use external beam radioscopy and chemotherapy. It plays a significant role in whole lung for pulmonary alveolar proteinosis, difficult intubation, delivering surfactant in ARDS and mucolytic in status asthmaticus, percutaneous tracheostomy and in the treatment of lobar atelectasis.

Airway obstruction due to malignant tumor can be cleared by tumor debulking using rigid bronchoscope that help in recanalization being ideal for coring through the tumor and dilating strictures, because of its larger internal diameter that facilitates ventilation and clot evacuation along with tumor debridement. Laser photoresection is often combined

bronchoscopically for endobronchial tumor arising from the wall of trachea or main bronchus stem. Laser photo resection using Nd:YAG laser is not undertaken with abnormal configuration profile, higher requirement of oxygen and unstable cardiovascular status, with absolute contraindications in patients with lesions affecting oesophagus or pulmonary vessels or the risk of fistula formation. Outcome in 79-90% of patients with improved airway patency is advised with laser photo resection, thus relieving symptoms of cough, dyspnoea and haemoptysis along with radio-endoscopic and spirometric achievement. Relief of haemorrhagic endobronchial tumors owes to coagulative feature of laser photo resection therapy. The relief of dyspnoea is immediate; thus, quality of life is improved. This procedure can be used complementary to chemotherapy, external beam radiation stenting or surgery often as the only means of palliative treatment. Caution must be used not to use combustible anaesthesia and using special masks and smoke evacuators to protect the treating chest physician as there are reports demonstrating intact lumen papillomavirus (HPV) DNA in vapours of laser treated verrucae and subsequent appearance of similar lesions in the treating doctors. Complications are seen in about 2% of patients such as perforation of major intrathoracic blood vessel, pneumothorax and pneumomediastinum.

Endo bronchial electrosurgery is another mode used through grounded bronchoscope for debulking tracheobronchial tumors by coagulation or vaporisation of tissue allowing 70-80% restoration of airway patency. Results are compatible with photo dynamic therapy in treating early lung cancers. Complications such as airway fire, hemorrhage and respiratory failure may occur. Airway perforation, pneumothorax and cardiac events like

## AN INTRODUCTION TO BRONCHOSCOPY

arrhythmias, hypotension or myocardial infarction may occur. Rare complications such as pulmonary oedema, airway scarring focal pulmonary hyperinflation and systemic or airway embolism can be prevented by following safety measures outlined. Radio frequency ablation can be useful in unresectable lung tumours. Port ablation syndrome, thermal injury, pleural effusion & pneumothorax are common complications. Tumours of upper lobe segment, superior basal lobar bronchi, stent-related granuloma causing obstruction and superficial haemorrhagic lesions can well be treated by non-contact electro-surgical argon plasma coagulator. The tissue necrosis achievement is not superior to Nd-YAG laser, photodynamic therapy or brachytherapy.

A local radiation treatment in the form of brachytherapy is very useful in small endobronchial tumors and provides quicker restoration of airway patency, especially when used along with laser photoresection. Otherwise multiple treatments may be required to be applied. It can be used after stent placement, patients having airway compression due to malignant tumors and also in the treatment of airway stenosis due to recurrent granulomatous tissue growth in lung transplant patients. Bronchoscopic brachytherapy has advantage and is often used in patients who have already received the maximal dose of external beam radiotherapy because of its capability to deliver the higher radiation dose directly to the tumor, sparing radiation of the tissue which is outside the treatment zone, dose localization and adaptability to the scope of the tumor. Complications include acute massive haemoptysis, fistula formation, radiation bronchitis, artery erosion, airway stenosis and respiratory compromise.

Cryotherapy is yet another method of applying -20 to -400 °C temperature cryoprobe bronchoscope to relieve airway obstruction caused by tumors both benign and malignant. Hypothermic cellular crystallization and micro thrombosis brings about local tissue destruction in the hyper-cryosensitive tumor cells. However repeat bronchoscopy after 8-10 days has to be done to clean up slough tissue. Even further repeat cryotherapy may be required for larger lesions. 30-60% relief in airway obstruction can be achieved and can well be combined both with chemo and radiotherapy. However, end tracheal cry therapy is ineffective in rapid clearance of tumor tissue, hence not a treatment of choice in life threatening tracheobronchial obstruction unlike laser photoresection and electro-surgery. Other indications include to treat granulomatous tissue, to remove foreign body, to clear mucus plug and blood clot and to treat web like stenosis. Complications include haemorrhage, tracheo-oesophageal fistula and pneumothorax.

Photodynamic therapy is used as a palliative treatment for advanced obstructive tracheobronchial cancers, providing better median survival as compared to other modes of therapy. However it can also be used for treating synchronous and early lung cancers. Therapy involves exercising two step process, using intravenous administration of photosensitizing agent followed by argon pump-dye laser exposure. Clean up bronchoscopy is often required 2-4 days after the procedure. 64-98% remission rate is obtained in squamous cell carcinoma that is radiographically occult and superficial i.e. <3 cm surface area and <1 mm in depth. Photodynamic therapy is superior for distal lobar obstruction where laser photo resection can't be done. However disadvantages of photodynamic therapy are that it cannot be used in patients with



## AN INTRODUCTION TO BRONCHOSCOPY

acute distress requires 4-6 weeks avoidance of sunlight and requires clean up frequent bronchoscopies. Dyspnoea (due to tissue oedema), photosensitivity and haemoptysis, are the common complications.

Therapeutic bronchoscopy is used to give relief in acute respiratory distress following laser photo resection or electrocautery dy placement of stent for malignant tracheo- bronchial obstruction. Dumon-silicone stent can be placed through rigid bronchoscope and has the advantages of easy repositioning and removal, relatively cheaper and providing solid barrier to prevent tumor encroachment. However disadvantages include lack of flexibility in tortuous airway, tendency to migrate, mucus retention, relatively unfavorable wall to lumen ratio and possible has the ability to stimulate formation of granulomatous tissue. Compared with these, metallic stents have the advantage of ease of placement, better conformity to tortuous airways, dynamic expandability, greater airway cross-sectional diameter, uninterrupted mucociliary clearance and viability and visibility on the radiograph. However, these have their own disadvantages like these are difficult to remove, stimulate granuloma formation and have difficulty in repositioning due to stent epithelialization. Airway or large vessel perforation has also been reported. However, covered metallic airway stents are safer and effectively useful in managing malignant tracheo-oesophageal fistulae allowing resumption of oral nutrition, reducing the risk of recurrent aspiration and hence improving the quality of life. Indian experience has found it to be relatively less invasive procedure to relieve airway obstruction and to close tracheo-oesophageal fistulae.

Benign airway obstruction due to haemangiomas, myoblastomas, lipomas, leiomyomas, chondromas, haematomas and histiocytomas can well be sealed with laser photo resection. It is useful in sealing the small proximal bronchopleural fistula occurring after lung resection by using yttrium-aluminum garnet laser. Wegener's granulomatosis, post tracheostomy tracheal granulation, or endobronchial amyloidosis can be managed either by laser photo resection or electrocautery or cryotherapy. Subglottic or tracheal stenosis can be treated with mucosa-sparing Nd-YAG laser photo resection, dilatation with balloon or single size rigid bronchoscope, stenting for malacia and recurrence of stenosis after three bronchoscopies may require surgical intervention.

Balloon bronchoscopy with fiberoptic bronchoscope, often combined with laser bronchoscopy and stent, placement is used to treat strictures due to tuberculosis, prolonged intubation, fibrosing mediastinitis and lung transplantation. Balloon dilatation allows time inflammatory stricture in lung transplant recipient to mature into fibrous stricture which is more suitable to stent placement. Dilatation of airway stenosis before stent placement allows assessing the extent of lesion, degree of inflation and status of bronchial tree distal to stenosis. Chest pain, bronchospasm, airway perforation, pneumothorax and pneumomediastinum are the common complications of balloon bronchoplasty.

Therapeutic flexible bronchoscopy is the first choice management in most of the cases of haemoptysis for better pin point localization of haemorrhage as well as employing endoscopic measures to control bleeding. Rigid bronchoscopy, if indicated, is the right choice procedure for massive haemoptysis that accounts

## AN INTRODUCTION TO BRONCHOSCOPY

for 4-11% of all patients with haemoptysis. Endobronchial tamponade is performed by wedging fiberoptics bronchoscopic tip into the bleeding segment, followed by balloon catheter inflation that is left in place for 24 hours, while bronchoscope is taken out, bronchoscopy is repeated after 24 hours if there is no bleeding, deflation of balloon is done, followed by catheter removal. This is quite safe, but if the inflated balloon is kept extended complications such as mucosal ischaemic injury and soft obstruction pneumonia may result. Modifications such as J- guide wire and double lumen bronchus blocking catheter have been introduced that can be wedged in the bleeding segment for a number of days without complications.

Fiberoptics bronchoscopy has been used in administering surfactant and liquid ventilation in case of ARDS, N-acetylcysteine for mucus plugging, and fibrin glue instillation into bronchial segment to seal broncho-pleural fistula. Bronchoscopy is a choice procedure in respiratory emergencies in intensive pulmonary units. In patients with compromised upper airways or in those with restricted neck mobility, it is used to guide placement of endotracheal tubes, without losing the control of airways. It's also useful in anaesthetized and paralyzed patient to ensure ventilation (C-jet ventilation) until the airways is secured. Fiberoptics bronchoscopic suction of thick mucus plugs and secretions help in facilitation the asthmatics to wean from mechanical ventilation in the ICU admitted patients. Although resulted hypoxia in whole lung collapse and lobar atelectasis cautions, but fiberoptics suction has been helpful in rendering oxygenation and radiological improvement in these cases. However, its superiority over chest physiotherapy has not been established.

Bronchoscopy has been utilized for percutaneous dilatation tracheotomy as a bad side procedure of needle puncturing trachea, followed by step-wise dilatation and placemen of tracheostomy tube. Unstable cervical spine, skin infection and raised intracranial pressure are absolute contraindications while coagulopathy, higher ventilatory requirements, obesity and of course goiter are the relative contraindication to the procedure. Complication rate is lesser than surgical tracheostomy, but they do occur, such as mucosal tear, haemorrhage, perforation causing tracheo-oesophageal fistula, paratracheal insertion, barotrauma leading to pneumothorax, pneumomediastinum and subcutaneous emphysema, damage of the endotracheal tube as well as fiberoptics bronchoscope, early dislodging and infection of stoma.

Flexible bronchoscope is used in removing foreign body under local anaesthesia. Rigid bronchoscopy is kept reserved if fiberoptic bronchoscopy fails. Bronchoscopy removal of loose broncholiths is recommended, with flexible bronchoscope. Since extensive granulation tissue is associated with broncholiths, it's removal often complicates with massive bleeding, pressing for the need of rigid bronchoscope. However, partially ended broncholiths have successfully been removed by flexible bronchoscopy YAG laser can be used to fragment large broncholiths and then subsequently fragments can be removed by fibre optic bronchoscope. Management in children should never be considered lightly because hypoxia can be fatal. It is difficult, yet a complimenting job between a pulmonologist and an anaesthetist.

## AN INTRODUCTION TO BRONCHOSCOPY

Therapeutic whole lung lavage to remove lipoproteinaceous material with repeated saline solution is the choice treatment in pulmonary alveolar proteinosis. This not only removes anti GM-CSF anti body, but also provides immunologic effects on the alveolar macrophages and type II pneumocytes. Hypoxemia and haemodynamic instability can occur during whole lung lavage. Therapeutic alternatives like segmental or lobar lavage have been put forth, where modified bronchoscope fluid may be required.

Mediastinal cysts, werer bronchogenic cysts account for more than half of the total mediastinal cysts that are 90% of all primary mediastinal masses, can be aspirated bronchoscopically through transtracheal or transbronchial routes, thus avoiding the need for thoracotomy or mediastinoscopy. An indwelling catheter can also be placed for continuous drainage and irrigation of abscess, with a precaution of not allowing spillage of pus into the airways.

Therapeutic bronchoscopy is expanding its application areas. Its assumed importance in palliative lung cancer management has seen the dream come true in providing relief to dyspnoea and stopping haemoptysis and thus ultimately quality of life is improved. It is useful with laser controlling pulmonary haemorrhage in children. It has cut short the need for mechanical ventilation and also assisted to allow time for institution of external beam radiotherapy and chemotherapy. Its significant role in difficult intubation, foreign body removal, treatment of lobar atelectasis, lung lavage for pulmonary alveolar proteinosis, administration of surfactant in ARDS and fibrin glue instillation in persistent bronchopleural fistula is worth mentioning. In the years to come, it will add life to life to diagnostic and therapeutic pulmonology and may be seen playing role in drug delivery

including gene therapy, utility of stents to manage central airway obstruction and bronchoscopic lung volume reduction to gain the effective lung volume reduction surgery without the need for surgery in patients with severe emphysema, thus expanding it's therapeutic role in the near future. The procedural proficiency and imparting training should never be compromised with patient's satisfaction and bronchoscopic yield. Nevertheless, committed bronchoscopic performance with some discomfort to the patient would be a better deal than a patient-comforting-non yielding bronchoscopic action.

-----  
-----

## PEDIATRIC BRONCHOSCOPY

Bronchoscopy in infants and children has been a routine procedure for over half a century. The operational area has shifted from rigid to flexible bronchoscopy in the last few years, signifying the genuine attraction of more of pediatric pulmonologists towards this sub speciality. Nevertheless, the indications, technique and even equipment are quite different from those being applied in adults.

Pediatric bronchoscopy has an outer diameter of 3.4-3.6mm, with a 1.2mm suction channel, which is not present in 2.2mm ultra thin flexible bronchoscope being used in neonates. Two types are available either a steerable version or with a suction channel but not both. However, smallest adult bronchoscope can be used in older children & adolescents, particularly when transbronchial biopsy has to be done or purulent secretions are to be removed. Cytology brush and mini forceps can be introduced, though, multiple specimens have to be taken. Even forceps with urologic basket can be used for removing foreign body.

Trained personal along with second physician are important part of pediatric bronchoscopy procedure. Chronologic recording of medications administered and complete supervision of procedure with maintenance of record of specimens collected during the procedure is important. The procedure is done under intravenous sedation, monitoring blood pressure, heart rate, and pulse oximetry as greater interference with gas exchange is likely to occur because of greater proportion of cross sectional area of trachea being occupied by bronchoscope. Thus safe pediatric flexible bronchoscopy in the presence of hypoventilation due to

intravenous sedation requires attending bronchoscopist to be efficient (to get the yield) to be dynamic (short time user with a watch on vital signs) minimizing the duration of inspection and avoiding any injury or other complication in a haste. Associated services of pediatric anaesthetist have made the procedure safe and effective. Separately as a bronchial wall while the rest ones are processed. Laryngeal mask is used in infants with significant respiratory insufficiency and also allows use of smaller adult bronchoscope in older children as it allows assisted ventilation as required in trans bronchial biopsy. The attached recovery room and critical care eye of anaesthetist beeps monitoring after the procedure and helps in managing post procedural complications.

Patient is usually allowed to be accompanied with the parents to remain less apprehended and reassured. Supine position is preferred. Intravenous line, monitor access and topical application of anaesthetic are gently continued before nebulized lidocaine is sprayed in posterior oropharynx. Intravenous sedation for desired effect is given, oxygen supplementation via nasal cannula is started and transnasal route (in majority of case) is preferred for insertion of scope. A second doctor is mandatory to be present to monitor the baby at the time the procedure is carried out and even after that, since blood pressure change persists upto an hour after the procedure. Preoxygenation and close vigil is essential since transient hypoxemia alteration in the blood pressure and bradycardia may necessitate the withdrawal of the instrument. The patency of nares is checked, adenoids & tonsils are observed for their size & position and bronchoscope is advanced to a position, just above the larynx. Topical lidocaine is re-sprayed onto vocal cords & adjoining area and then scope is passed through cords. Further topical anaesthesia is sprayed into

## AN INTRODUCTION TO BRONCHOSCOPY

tracheobronchial tree before a thorough lower airways inspection is done.

Paediatric flexible bronchoscopy is indicated in airways obstruction, stridor, atypical wheeze, snoring or noisy breathing. Sometimes it may be used in identifying vocal cord adduction. Dysfunctional swallowing in suspected aspiration is another indication. This can also be done to inspect and perform BAL in cases of persistent undifferentiated lung lesions on plain chest x-ray. The bronchoscope is wedged in right middle lobe or above. 3x1ml/kg aliquots are used and the first one is processed as alveolar washes, sending these for cytologic & microbiologic studies. Oxygenation to the child has to be continued since BAL causes impaired gas exchange for several hours. The procedure is being used for surveillance in immune compromised patients without even waiting for abnormal chest x-ray.

Transbronchial biopsy may be indicated in case of unusual lung parenchymal disease and rejection after lung transplantation. It is rarely used to diagnose opportunistic infection since tissue samples are small and chances of complications such as bleeding and pneumothorax are increased. Transbronchial brushing as well as forceps biopsy are contraindicated in uncontrolled bleeding diathesis and in severely compromised child as in latter case, any bleeding or swelling following the procedure would risk complete respiratory obstruction. Renal failure is also a relative contraindication.

While brush biopsy is done in case of getting microbial yield and in conducting ciliary studies in primary ciliary dyskinesia, forceps biopsy is indicated in chronic inflammation, endobronchial tumour

and suspected granulomatous disease. It is increasingly used in removing foreign bodies where rigid bronchoscopy was virtually always indicated.

Paediatric flexible bronchoscopy is contraindicated when procedural risks outweigh the potential benefits or where it's difficult to maintain gas exchange in the presence of respiratory failure in an infant if the flexible bronchoscope is inserted. However, laryngeal mask anaesthesia has permitted bronchoscopy with ventilation in younger patients. While use of laryngeal mask technically is the easiest method but it does not allow inspection of upper airways & most of the larynx, & use of endotracheal tube allows deep anaesthesia and the best control of the airway especially in procedures like lavage & biopsy and also allows inspection of structures at or below the carina, the use of facial mask remains the most demanding for the anaesthetist, allows spontaneous child-breathing, full length airways inspection, dynamic changes in airways calibers being appreciated and forms a technique of choice for problematic children with stridor, upper airway obstruction & obstructive sleep apnoea. Coagulopathy remains a strong contraindication to transbronchial biopsy. Similarly, the procedure has more risk in children with cardiac failure, severe hypoxia and severe pulmonary hypertension. A small baby with preexisting airway compromise as in stridor procedure faces more of problems.

Patient discomfort and transient hypoxemia remain the commonly encountered complication. Addition of BAL has led to another important complication of fever, 4 to 12 hours after the procedure. Though rare, life threatening complications include pneumonia, bleeding, pneumothorax, respiratory failure and even death.

## AN INTRODUCTION TO BRONCHOSCOPY

To establish basic competency, 50 paediatric bronchoscopies successfully performed under supervision is necessary which has to be performed by dedicated operator, more than 25 procedures per year to maintain competency.

Further innovative procedures applied to paediatric flexible bronchoscopy include BAL, cytology brush, transbronchial biopsy, airway ballooning & stenting, laser therapy, segmental drug instillation, assessment of inflammation in lower airways & bronchography.

In intensive care, while monitoring sick children, pediatric bronchoscopy can be indicated in doing endobronchial toilet which can be combined with endobronchial rhDNase instillation, selective bronchial intubation, positioning & checking the endotracheal tube patency, facilitating difficult intubation, diagnosing ventilator associated pneumonia, asserting lobar collapse & assessing airway stenting and postextubation stridor or failure to wean and detecting new complications of intensive care.

### Comments:

FOB in Children is emerging alongwith rigid bronchoscopy as a primary mode for it's safer use in a small & sick infants. FOB also allows easy reach to upper lobes as compared to rigid bronchoscopy which is preferred for extraction of foreign body of trachea or bronchus, evaluating tracheal oesophageal fistula, laryngoesophageal cleft and pilateral abductor paralysis of vocal cords. FOB in pediatric population is being increasingly used both for diagnostic and therapeutic indications, given below in tables I&II.

**Table I**

### **Diagnostic indications of FOB in children**

- Persistent strider/wheeze/pneumonia
- Atelectasis
- Compression of trachea/bronchus
- Foreign body aspiration
- Pneumonia in immune compromised host
- Localized hyperinflation
- Haemoptysis
- Vocal cord paralysis
- Evaluating tracheostomy

**Table - II**

### **Therapeutic indications of FOB in children**

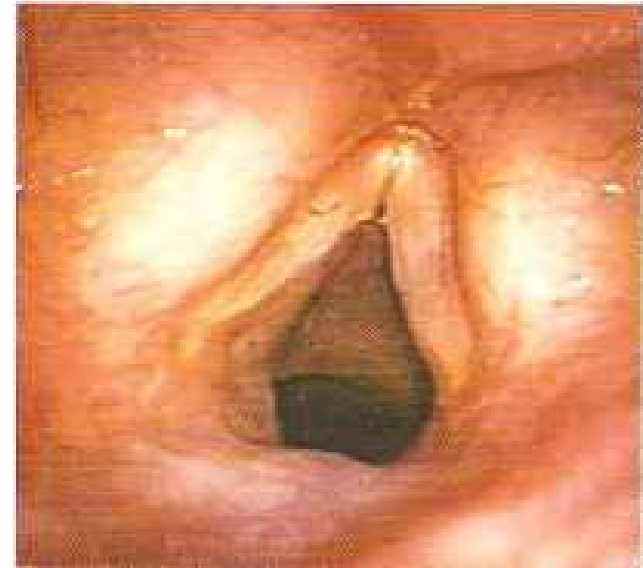- Removing mucus plug/bronchial cast/foreign body
- Difficult intubation
- Endobronchial biopsy
- Therapeutic lavage

-----  
-----

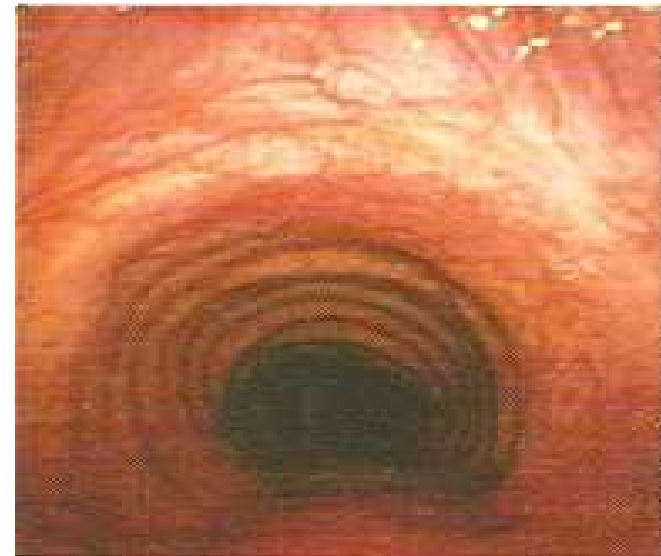### ENDOBRONCIAL ULTRASOUND (EBUS)

Offers a new innovative, cost effective, valuable technical development which helps mediastinal lymph node a staging of lung cancer when used as EBUS-transbronchial needle aspiration and may reduce the need for more morbid & costly invasive procedure. It's role may further be evaluated in India having higher prevalence of tuberculosis. Peripheral lung lesions can be biopsied in place of fluroscopic guided biopsy.

Two types of EBUS, radial & linear (Convex) are being used; having transducer (to produce & receive sound waves) and processor (to integrate the reflected sound waves). EBUS, thus, can be used to assess the extent of airway invasion, peripheral intrapulmonary lesions and analysis of mediastinal lesions. EBUS-TBNA has 85-96% of sensitivity in primary diagnosis of saroidosis, without any complication risk of bleeding, pnemothorax which is 2% & 5% respectively in case of transbronchial lung biopsy. Radial probe is useful in assessing airway invasion by tumours and in peripheral lung lesions while linear probe offers real time guidance for sampling mediastinal lesions.

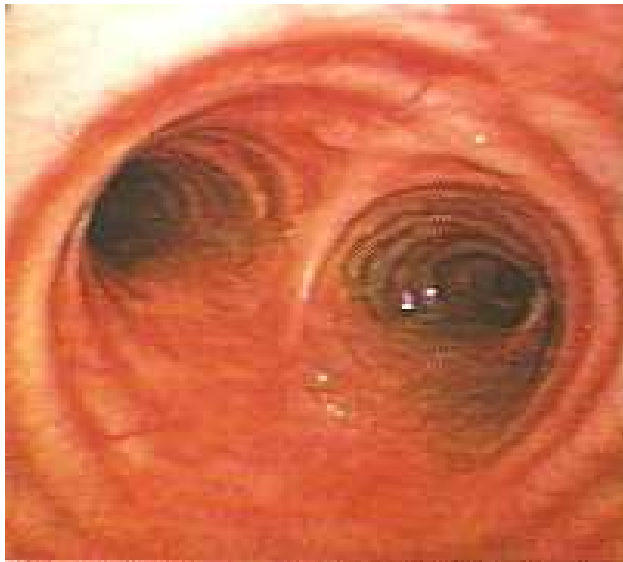

**Bronchoscopy showing normal Local Cords.**

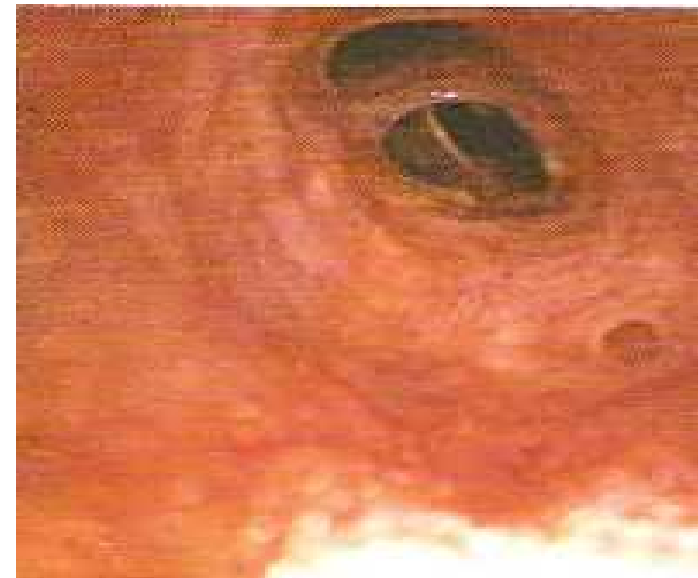

**Normal Adult trachea.**

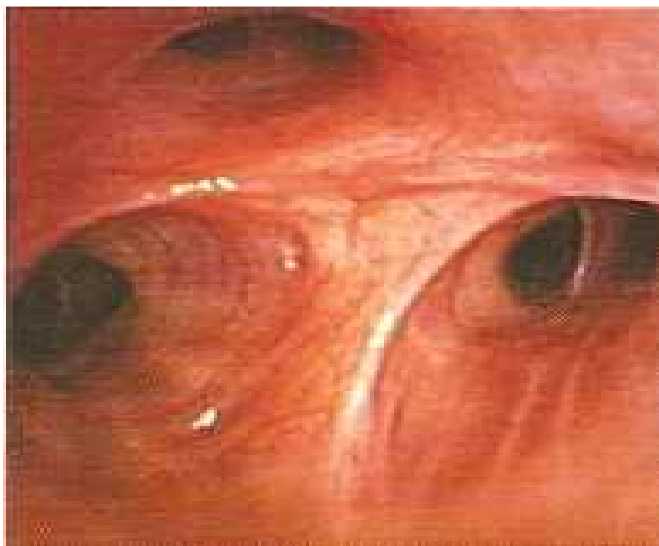AN INTRODUCTION TO BRONCHOSCOPY



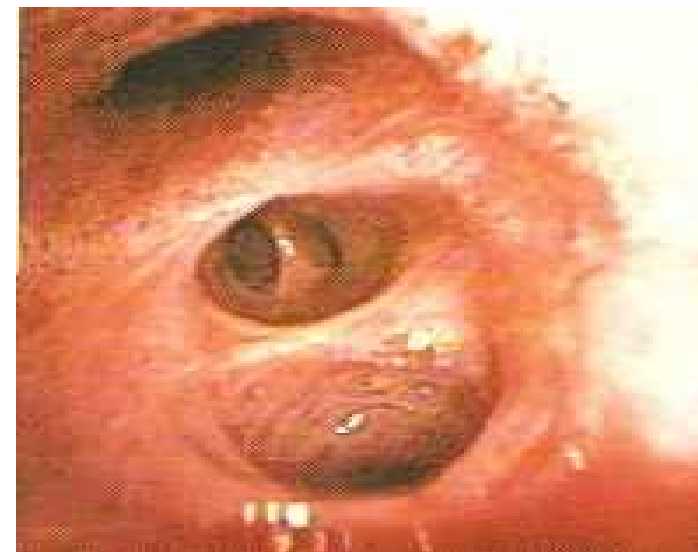**Normal Carina with tracheal bifurcation.**



**Medial & lateral segmental bronchi in right middle lobe.**



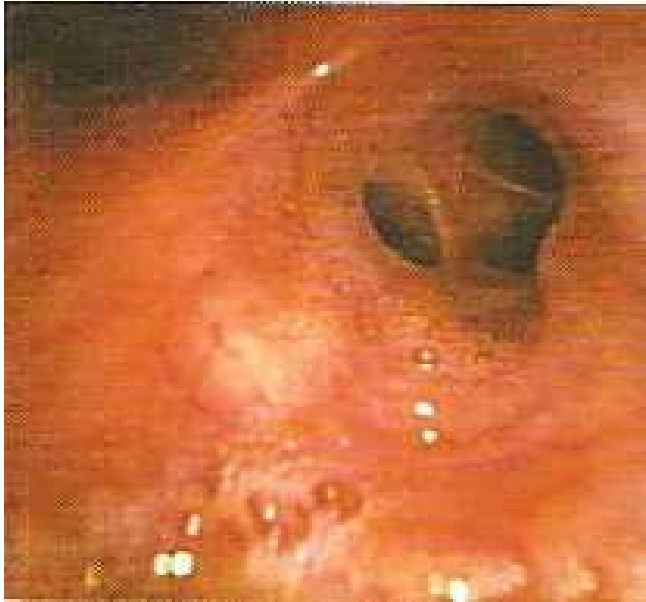**Apical anterior and posterior segmental bronchi.**



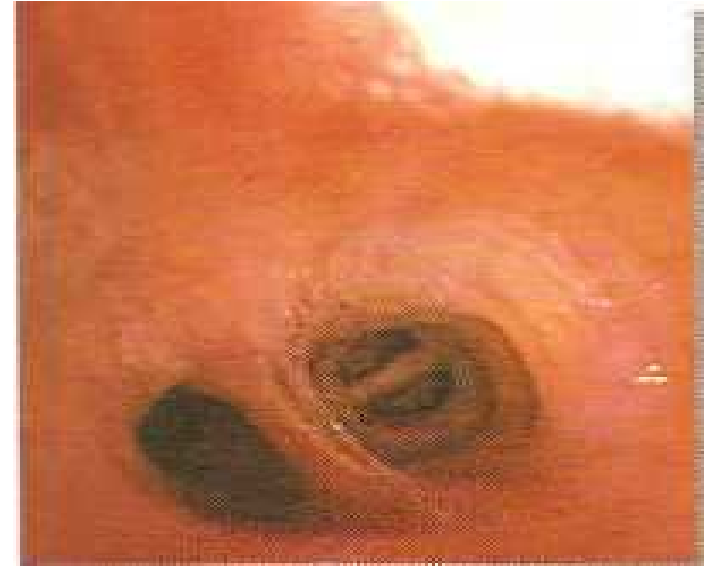**Five subsegmental bronchi in right lower lobe.**



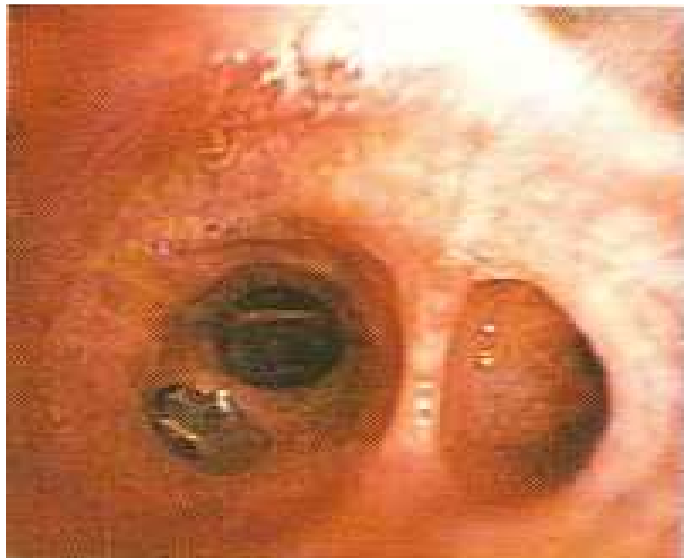AN INTRODUCTION TO BRONCHOSCOPY



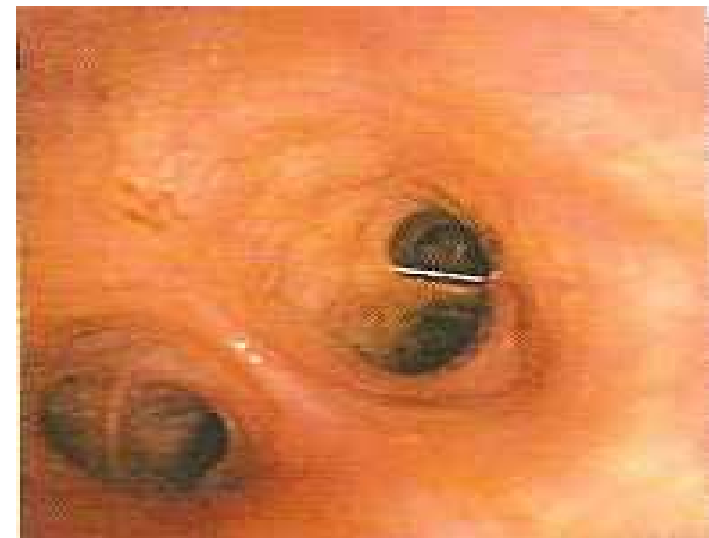**Anterior, lateral and posterior basal segments in medial basal sub-segment.**



**Superior and inferior sub-lingular subsegmental bronchi of lingular division of left upper lobe.**

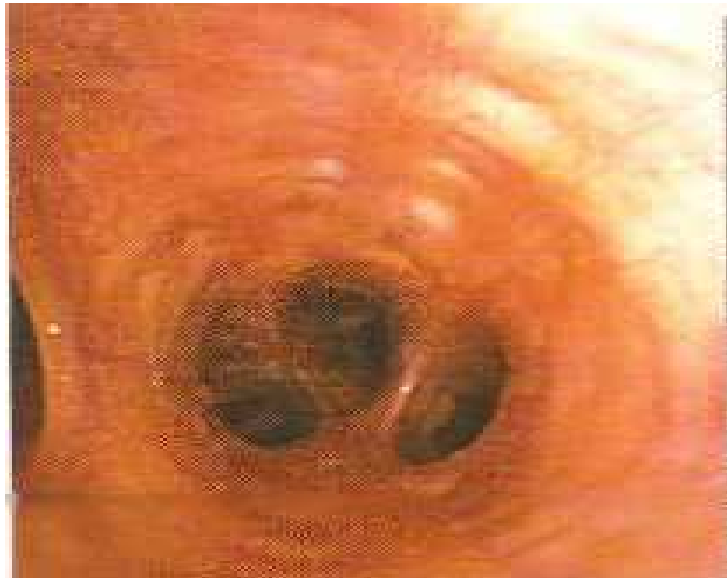


**Apicoposterior and anterior segmental bronchi of left upper lobe.**

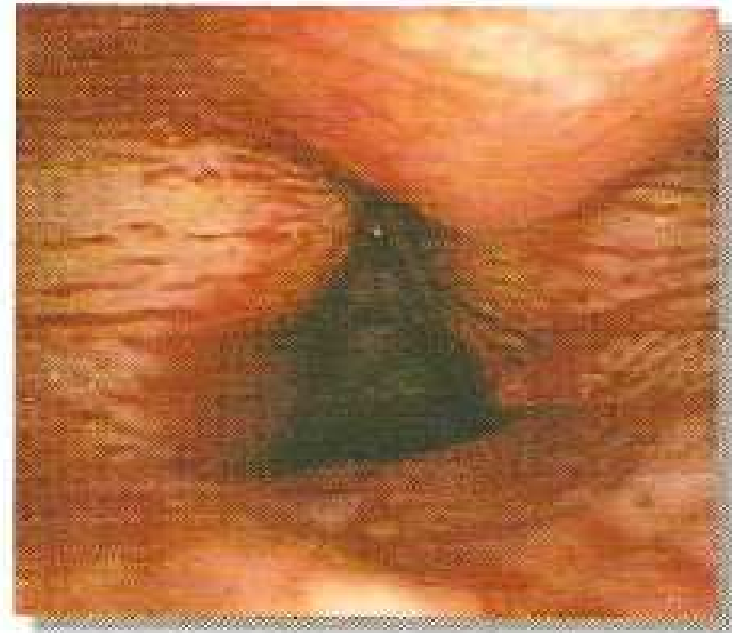


**Posteriorly located superior/apical segment of left lower lobe.**

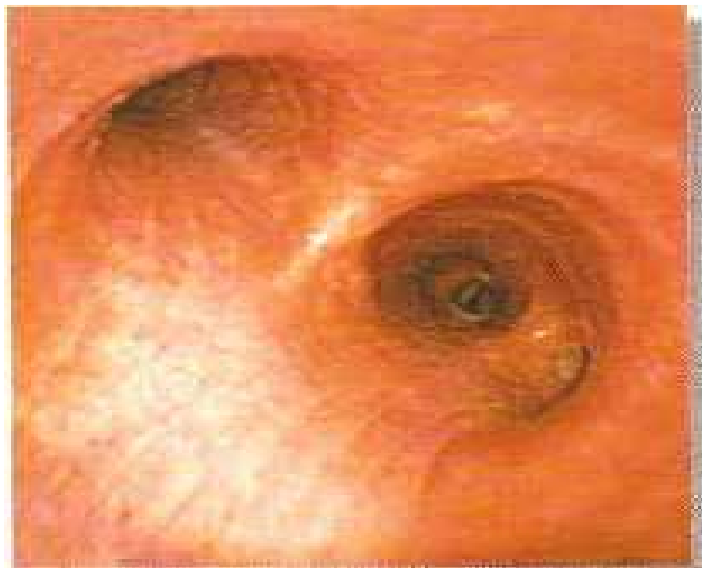**AN INTRODUCTION TO BRONCHOSCOPY**



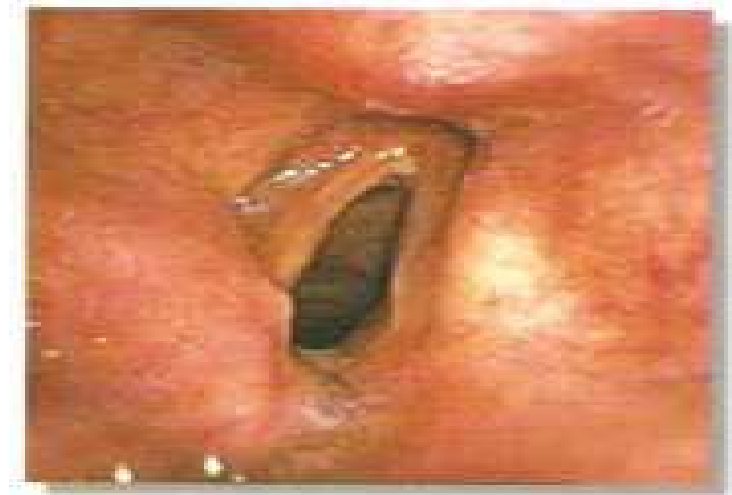**Anterio, lateral and posterior basal segments of left lower lobe.**



**Fresh blood or vocal cords in active haemoptysis.**

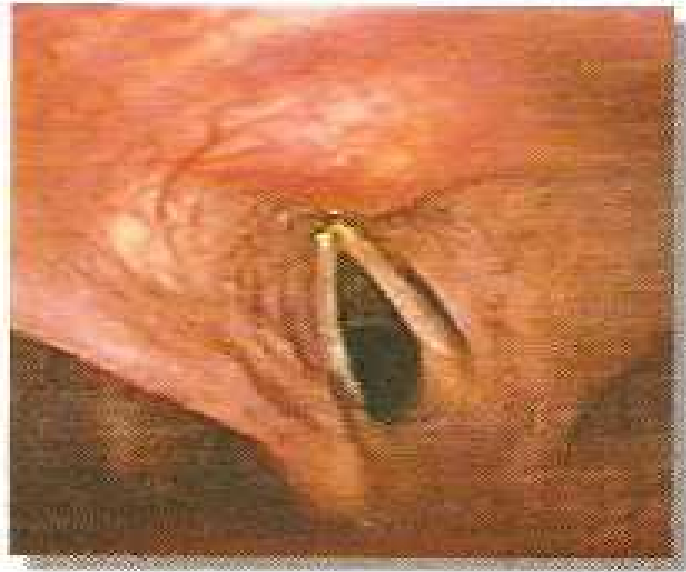

**At the level of Carina a normal variant is accessory bronchus.**

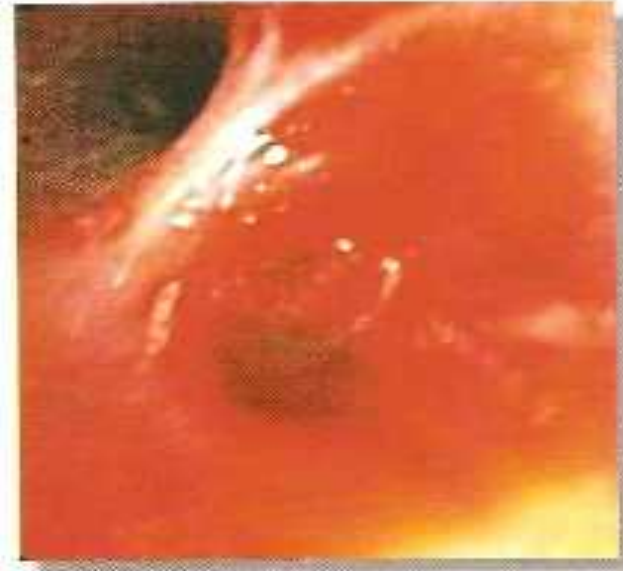

**Vocal Cords palsy of right side.**

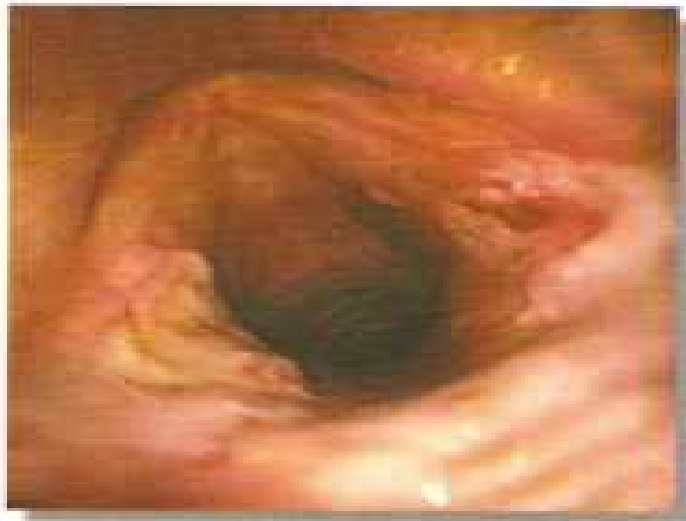AN INTRODUCTION TO BRONCHOSCOPY



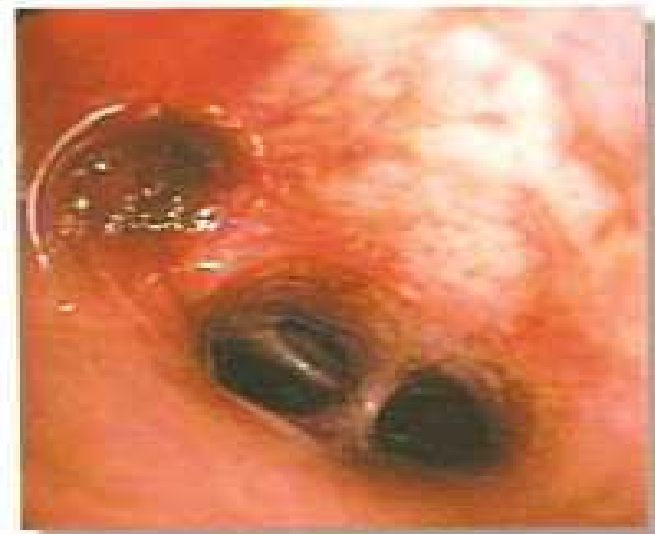**Vocal Cords palsy of leftside.**



**Right lower lobe with active massive bleedings (incase of squamous cell lung carcinoma)**

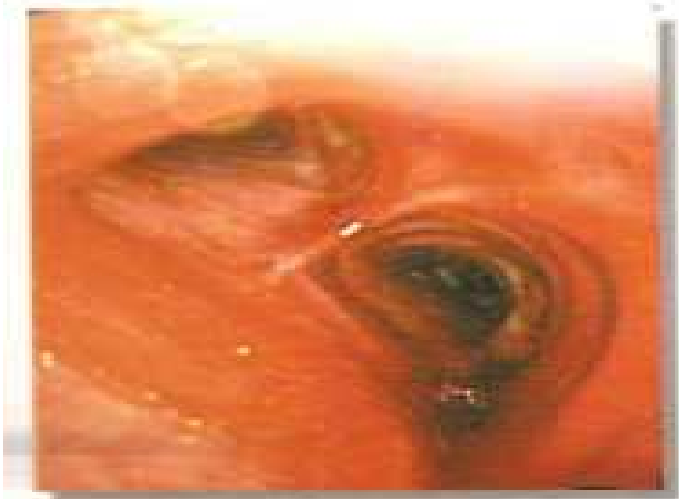

**Prolonged endotracheal intubation causing pressure ulcers on vocal cords.**

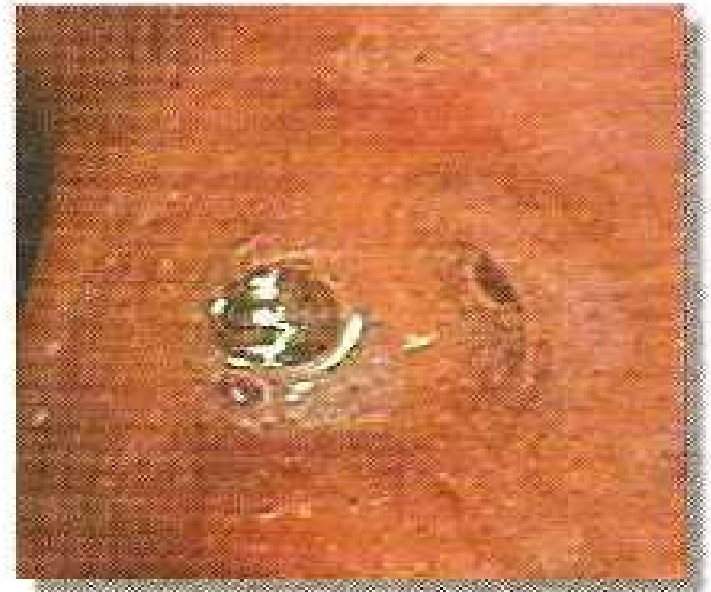

**Left lower lobe superior segment blocked due to fresh blood Clot**

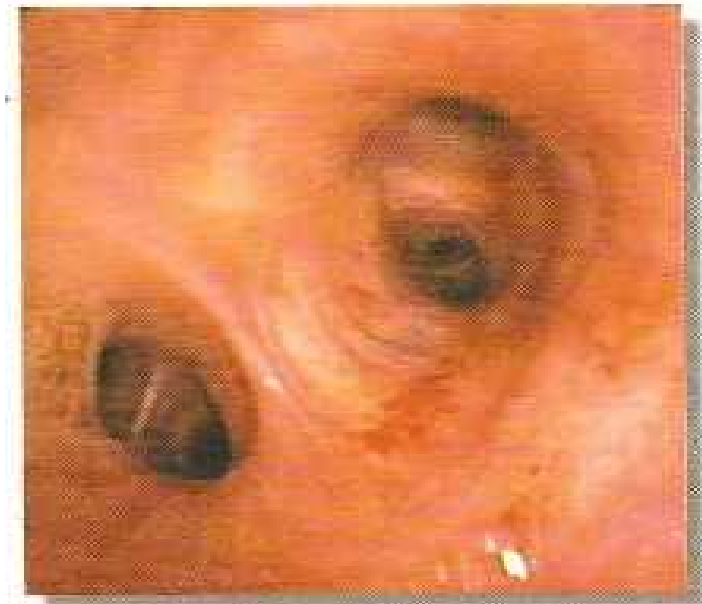AN INTRODUCTION TO BRONCHOSCOPY




**Lower end of trachea and carina – bleeding from mucosal injury caused by endotracheal suction.**



**Right middle lobe bronchus with mucoïd secretions.**



**Bronchoscope showing petechial haemorrhage.**

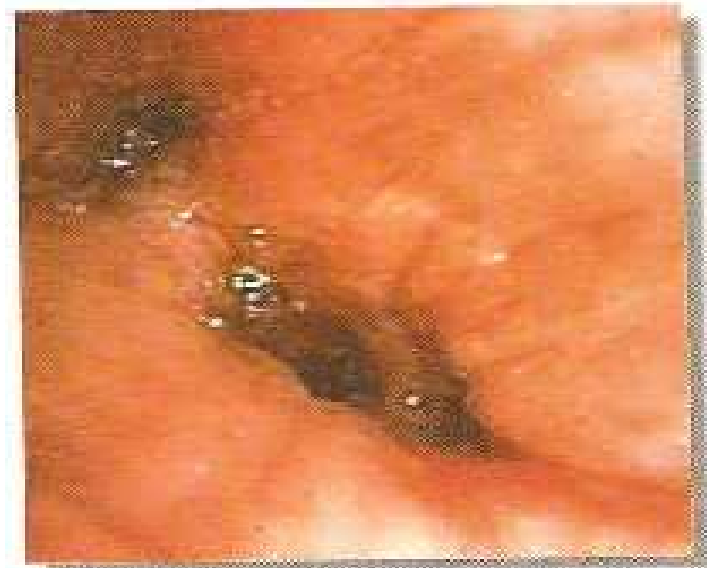

**Purulent secretions blocking left upper lobe bronchus.**

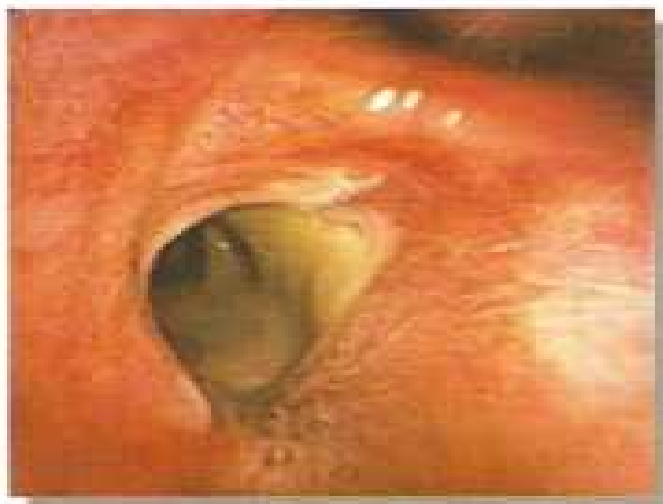AN INTRODUCTION TO BRONCHOSCOPY



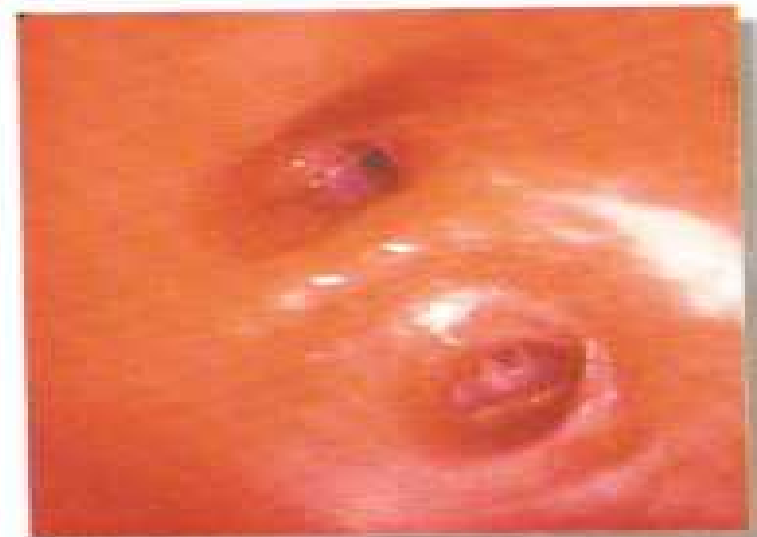**Trachea with purulent flakes.**



**Cold mucosal oedema, hyperaemia with oozing blood.**

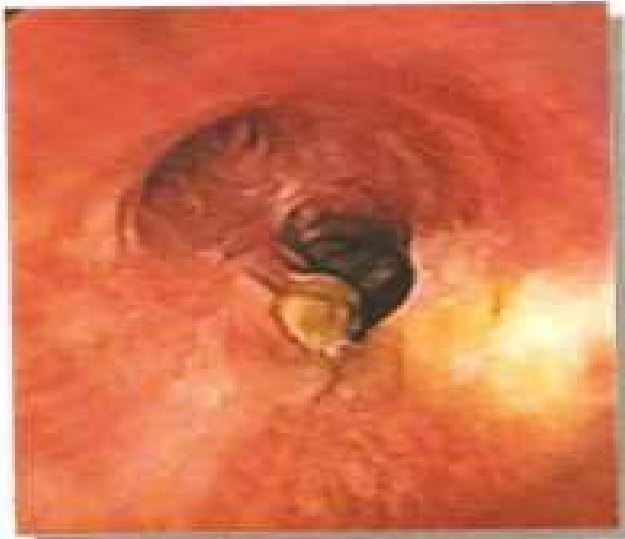

**Left lower lobe bronchus with creamy secretions.**

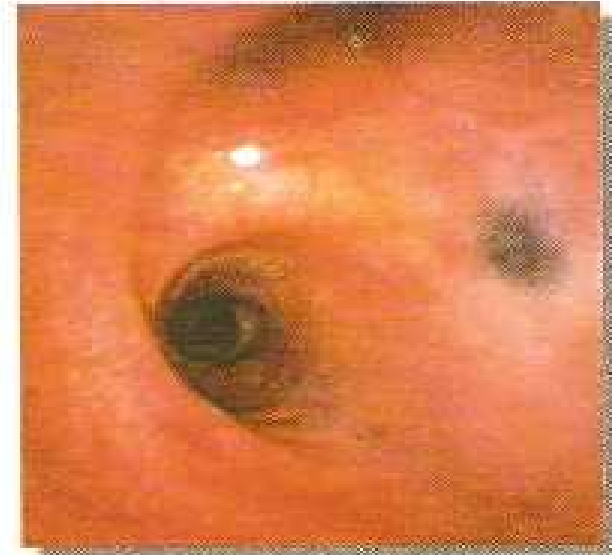

**Pneumonia acute inflammation of left upper lobe showed oedema, hyperaemia and oozing mucosa.**

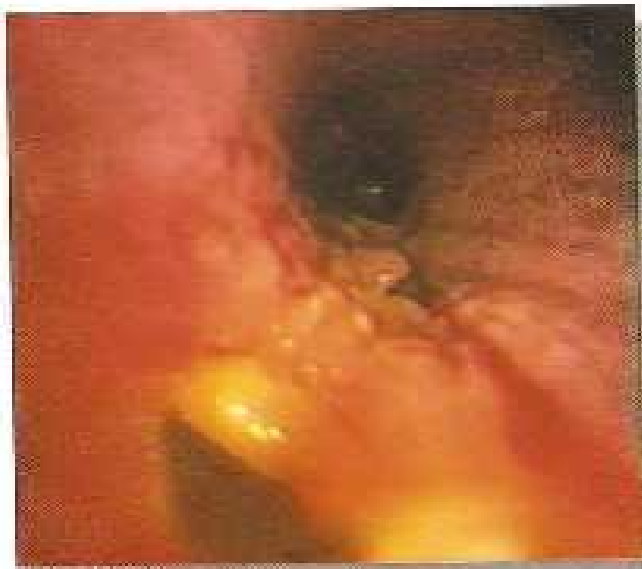AN INTRODUCTION TO BRONCHOSCOPY



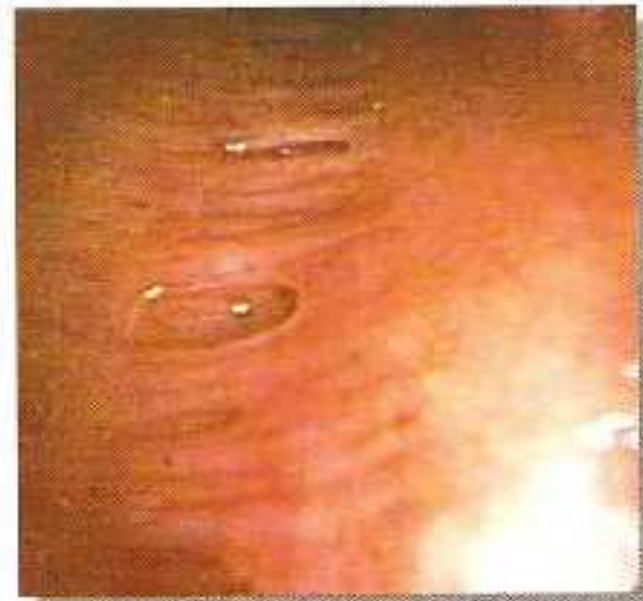**Chessy slough in tubercular inflammation.**



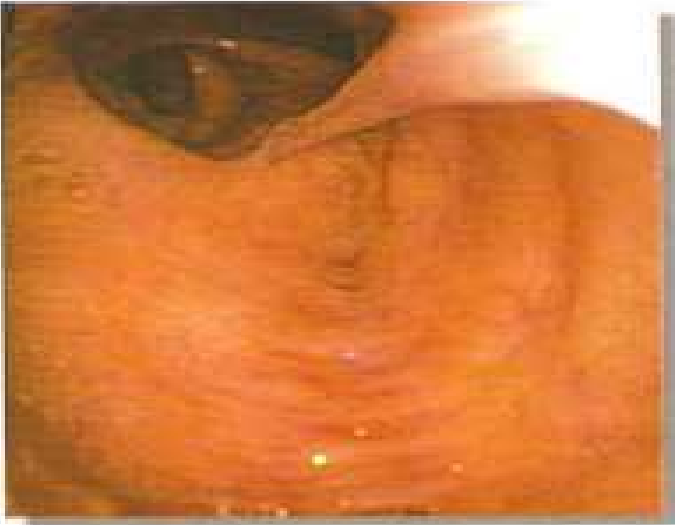**Right major bronchus with smoke soot in copd.**



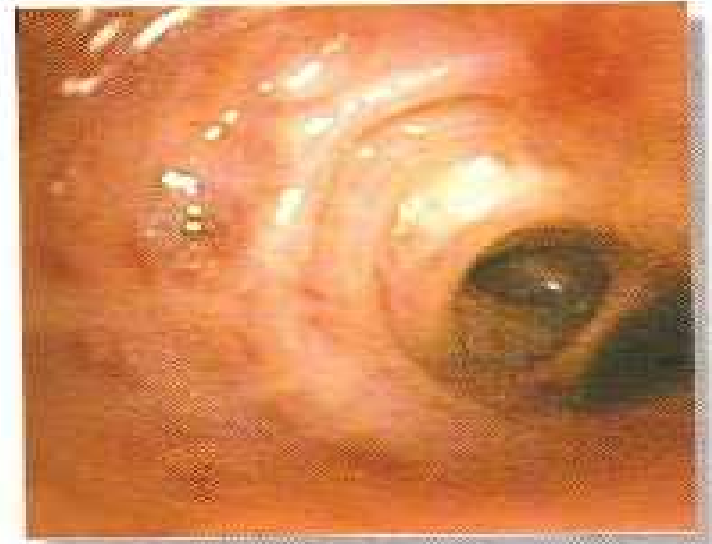**Foreign body with surrounding inflammation.**



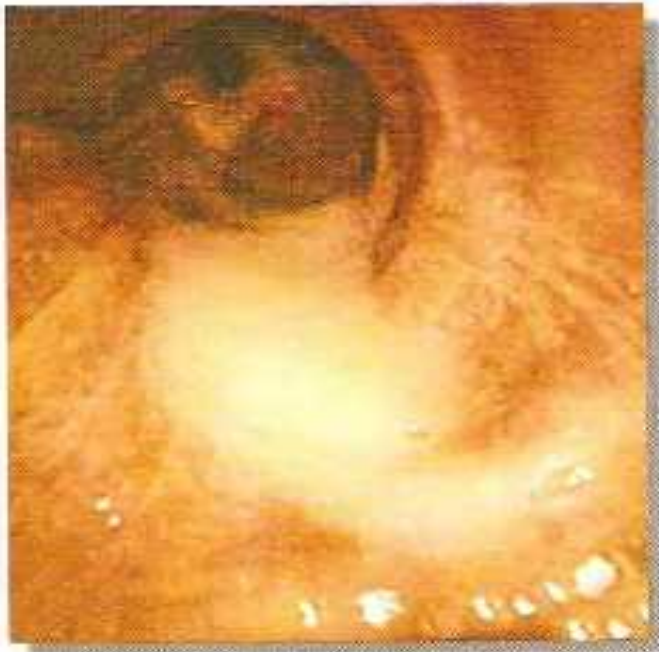**Mucous gland pits/diverculae.**



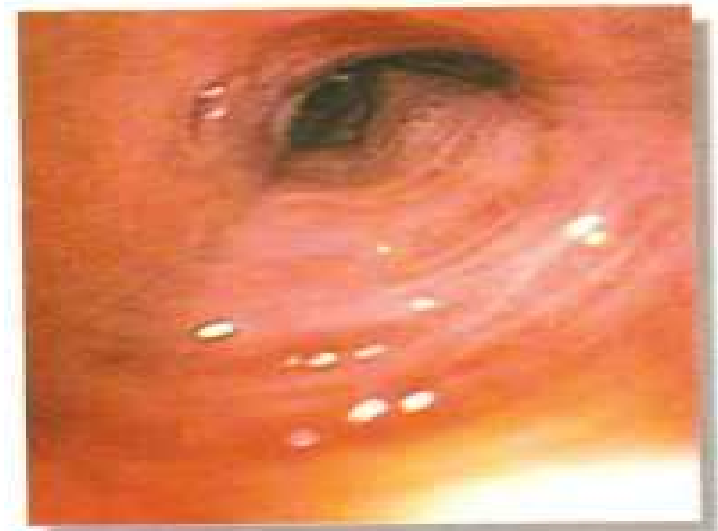**Tenaceous mucoid secretions.**



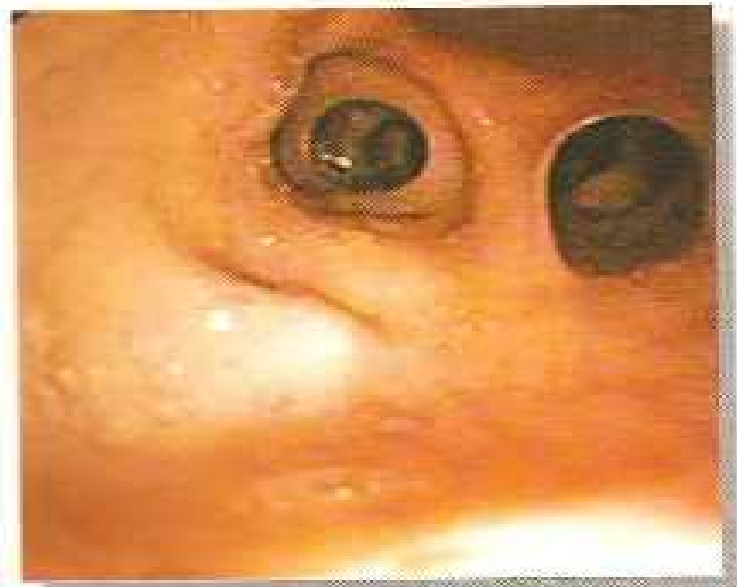**Mucopurulent secretions in dilated/cicatrized mucosa in bronchiectasis.**



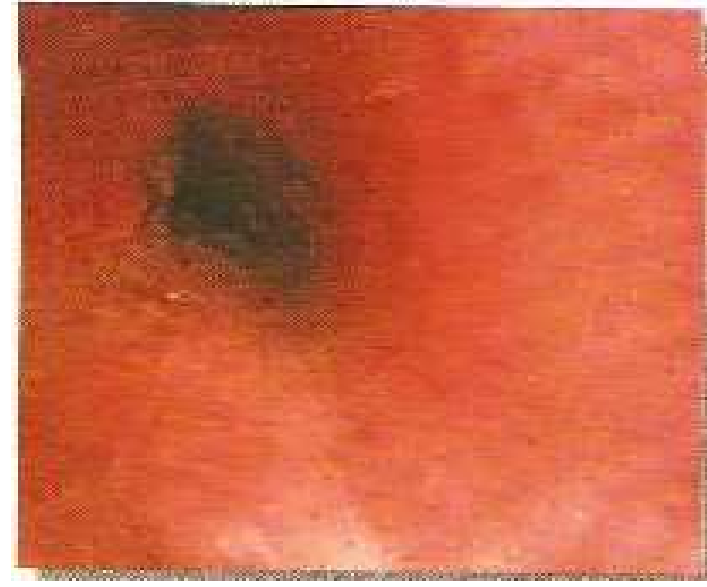**Purulent bronchitis.**



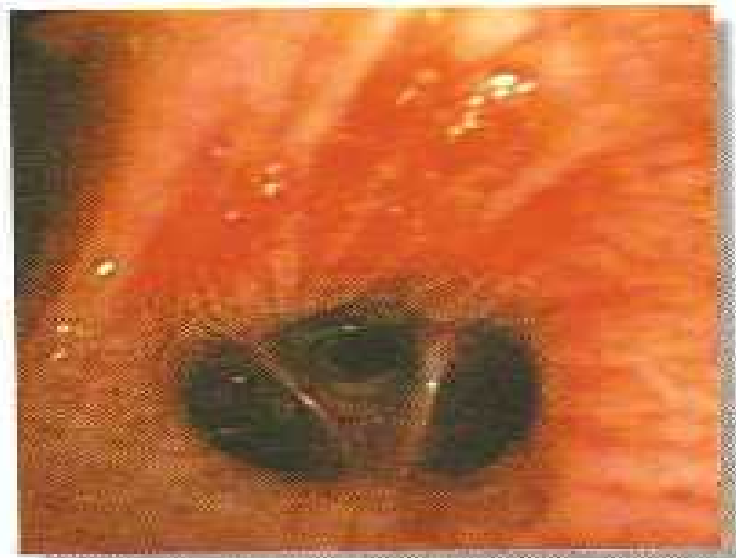**Dilated, cicatrized hyperaemic bronchial mucosa.**



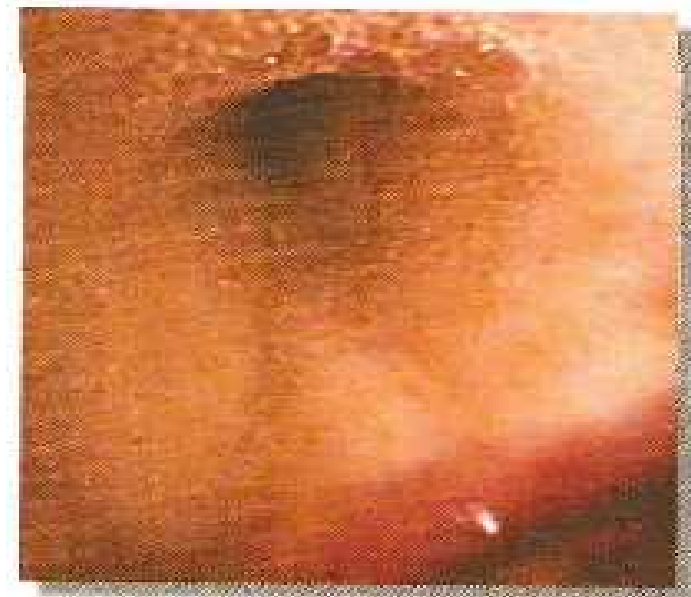**Right upper lobe with purulent bronchiectasis.**



**Left lower lobe showing stricture with granulation in tuberculosis.**

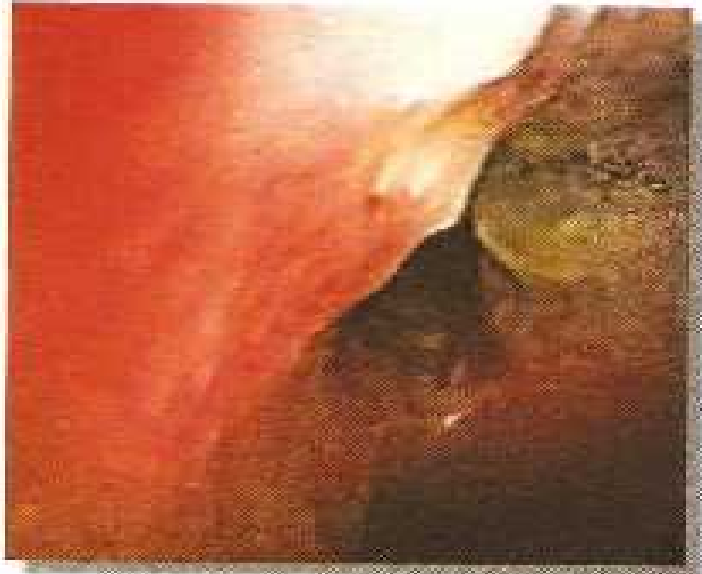

**Dry bronchiectasis with haemorrhage.**

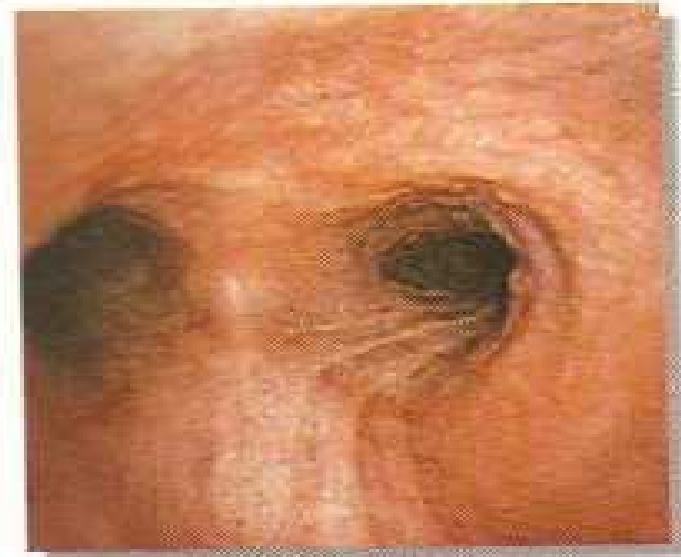

**Cheesy tubercular secretions.**

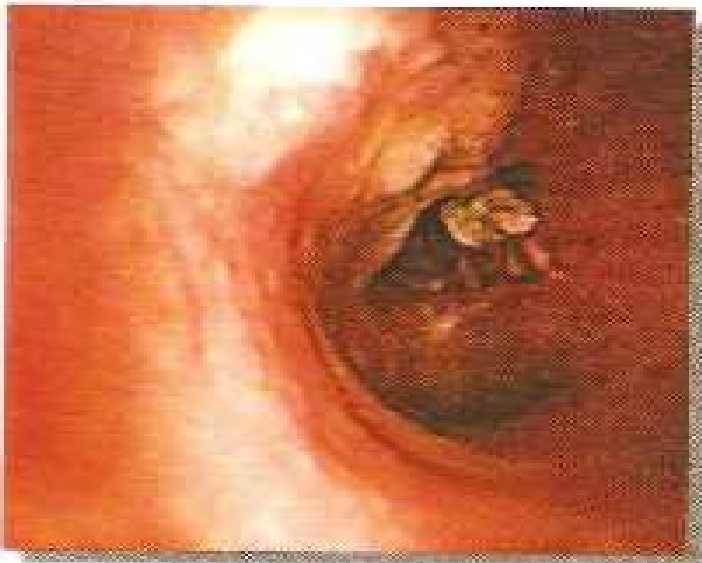



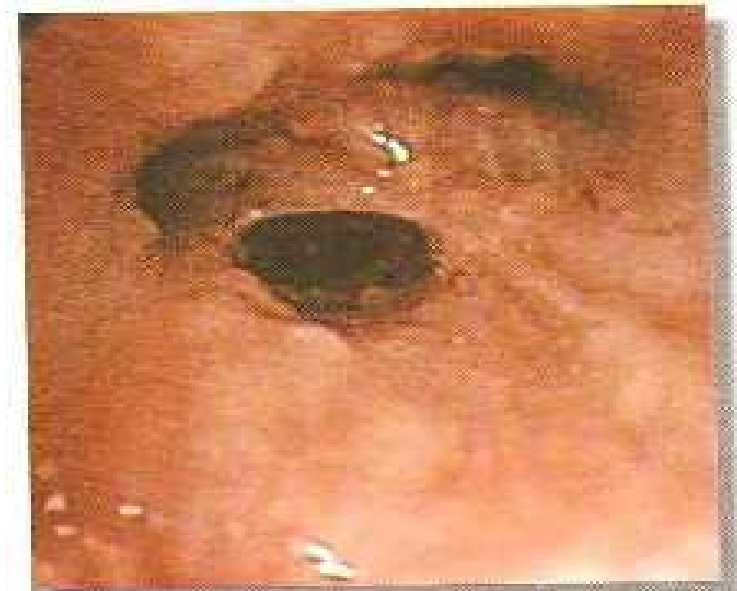**Right major bronchus with cheesy secretions from eroded mediastinal lymph node.**



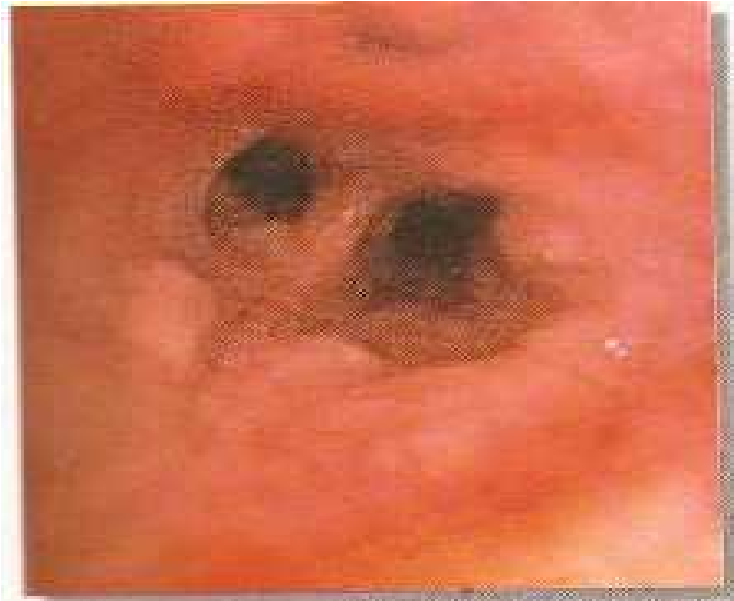**Widened carina with sarcoid granuloma.**



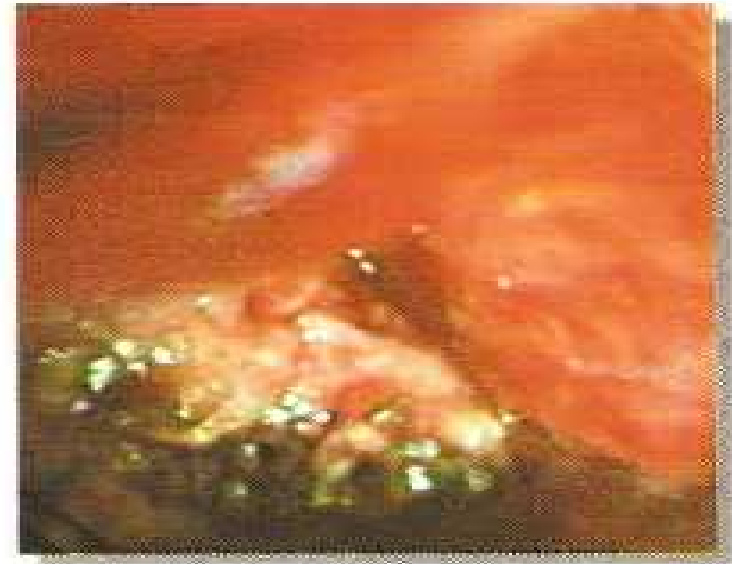**Tubercular ulcer with cheesy slough from mediastinal lymph node.**



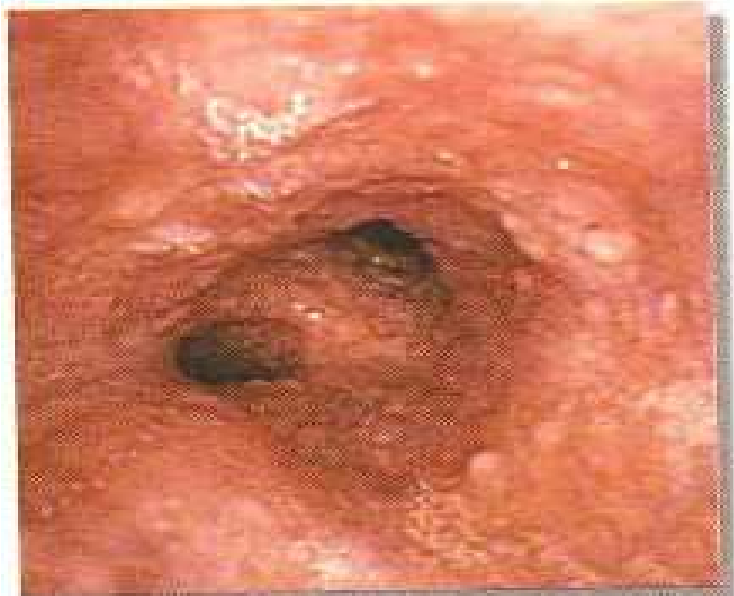**Sarcoid granulomas in right upper lobe bronchus**



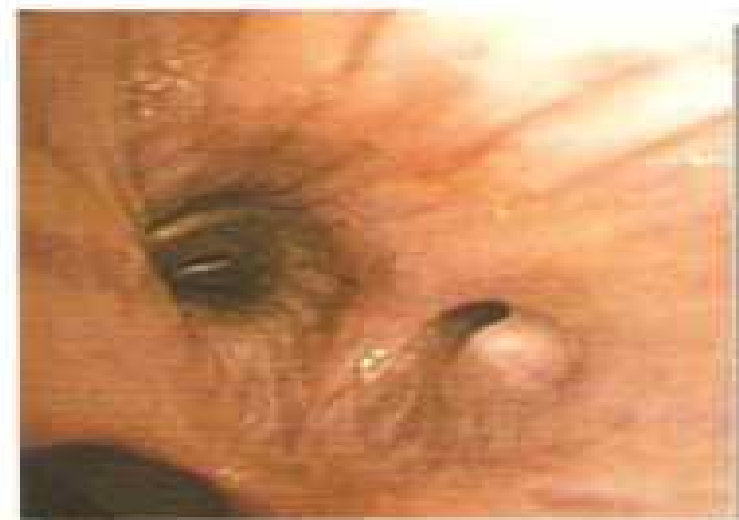**Larger sarcoid granulomas in right lower lobe bronchus.**



**Left major bronchus showing fungating growth**

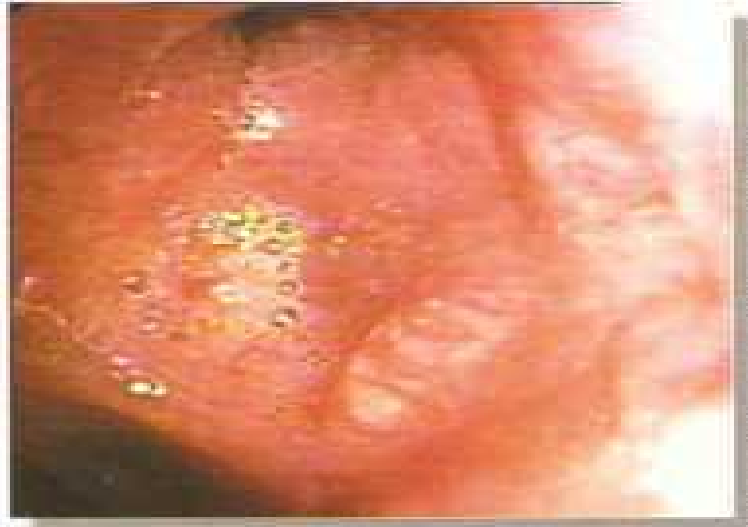

**Tracheal granulomas**

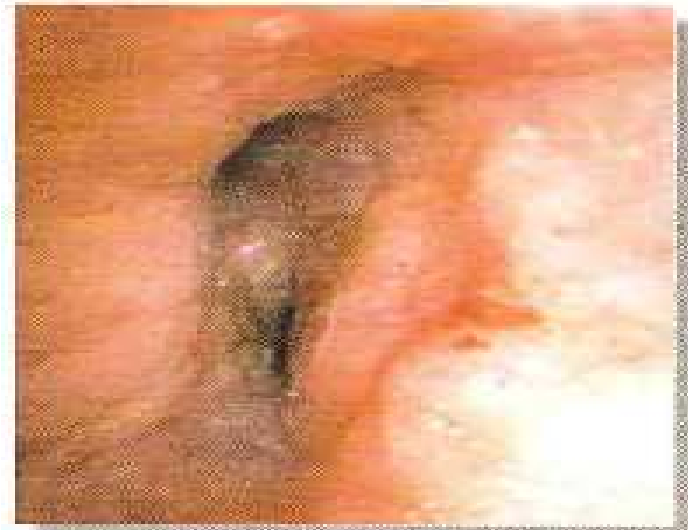

**Right lateral basal segment showing smooth nodular carcinoid**

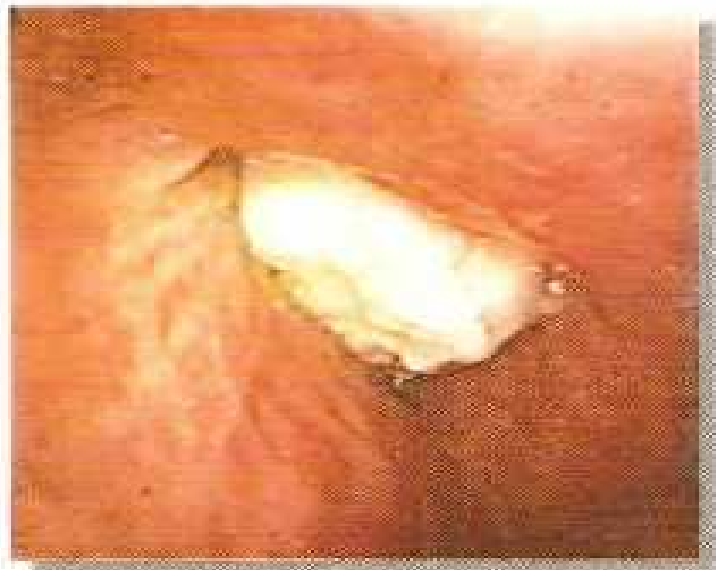AN INTRODUCTION TO BRONCHOSCOPY



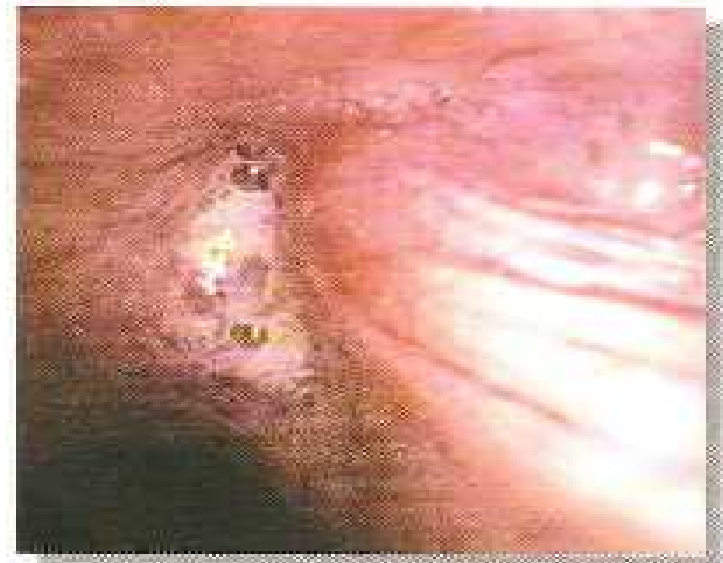**Left upper/lower lobe showing carcinoid smooth overgrowth**



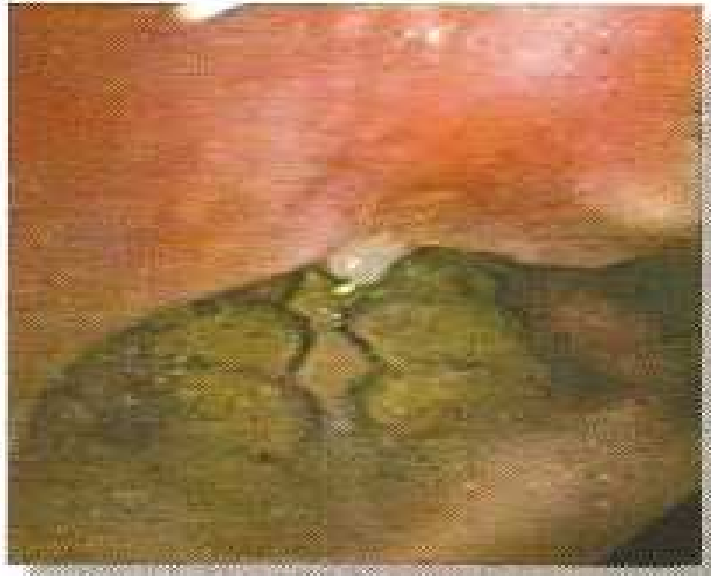**Left upper lobe bronchus showing mucosal extrinsic compression.**



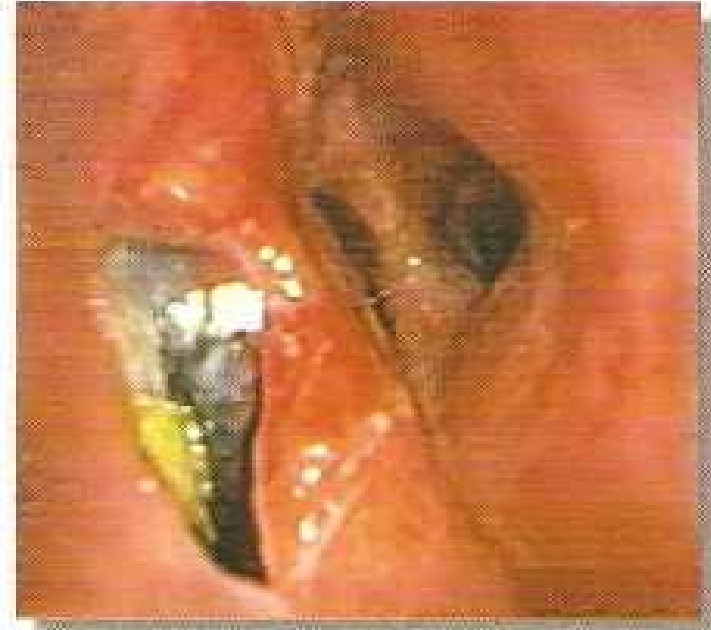**Left major bronchus showing purulent slough over a growth**



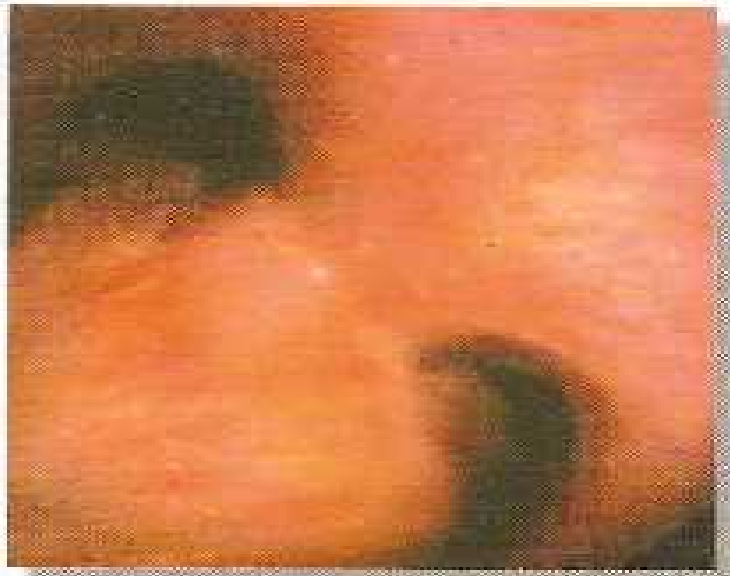**Right major bronchus both with smooth extrinsic compression and obstruction due to mucoid secretions.**



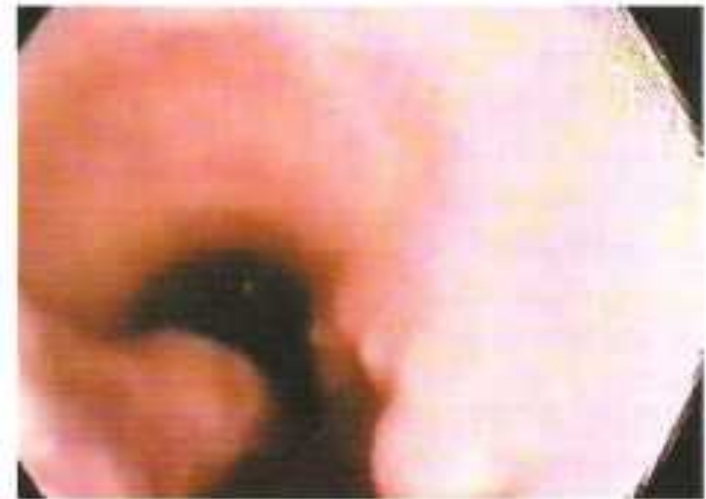**Tracheoesophageal fistula due to carcinoma oesophageal**



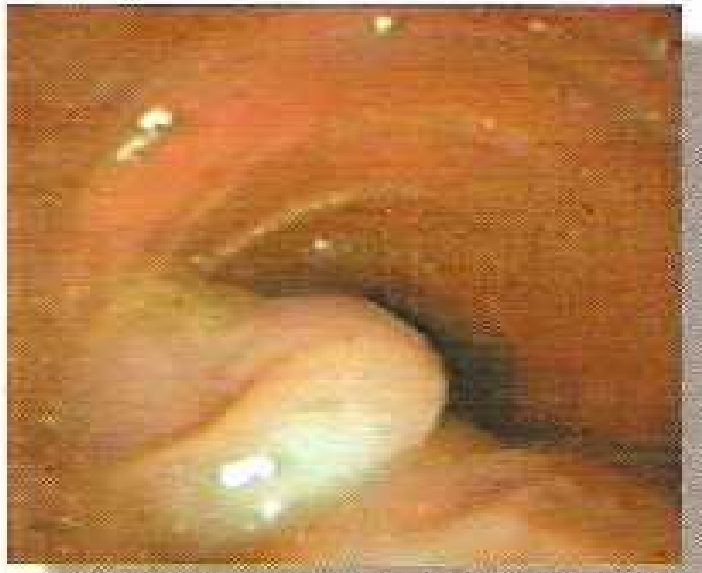**Bronchoesophageal fistula due to carcinoma esophagus.**



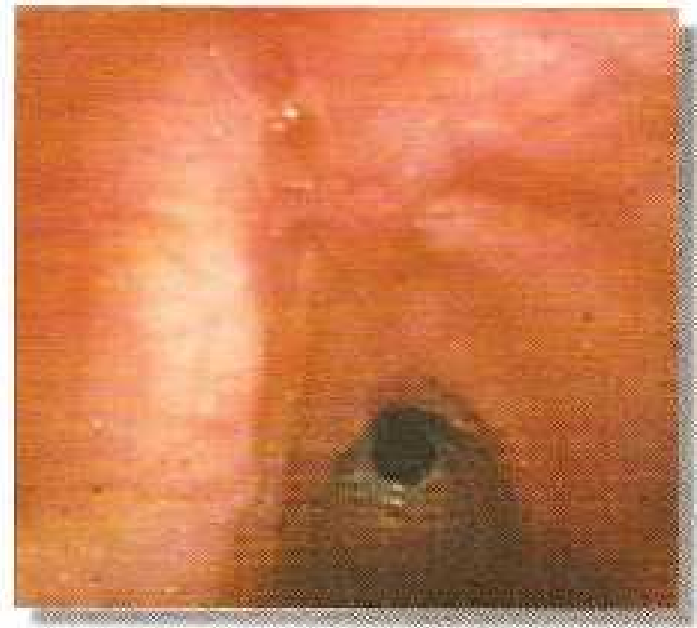
**Lymphoma affecting subcarinal lymph node, leading to widened carina.**



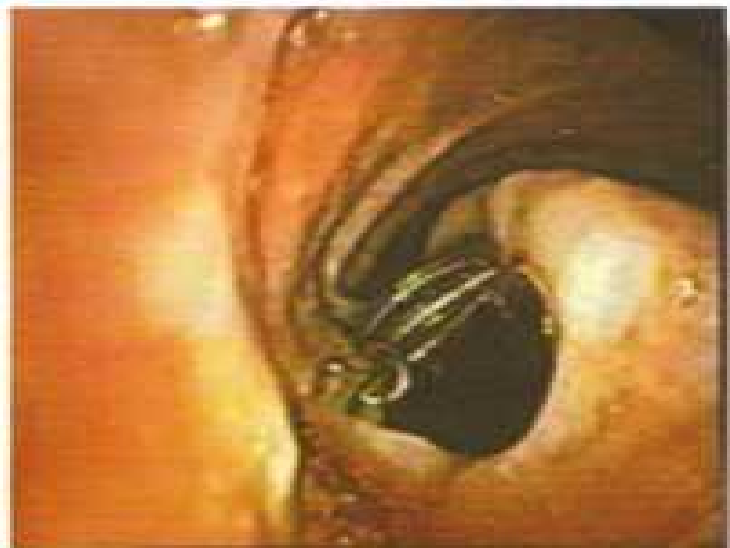**Gastrotracheal fistula following total esophagectomy with gastric pull up surgery.**



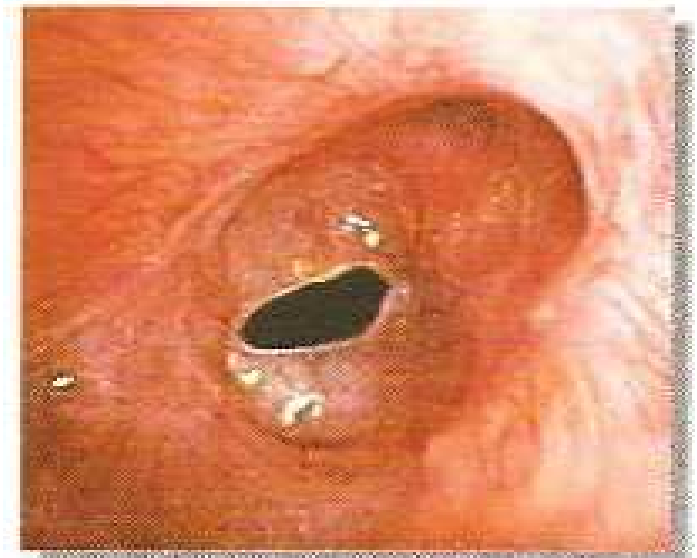**Prolonged endotracheal intubation causing benign tracheoesophageal fistula.**



**Post tracheostomy tracheal stenosis.**

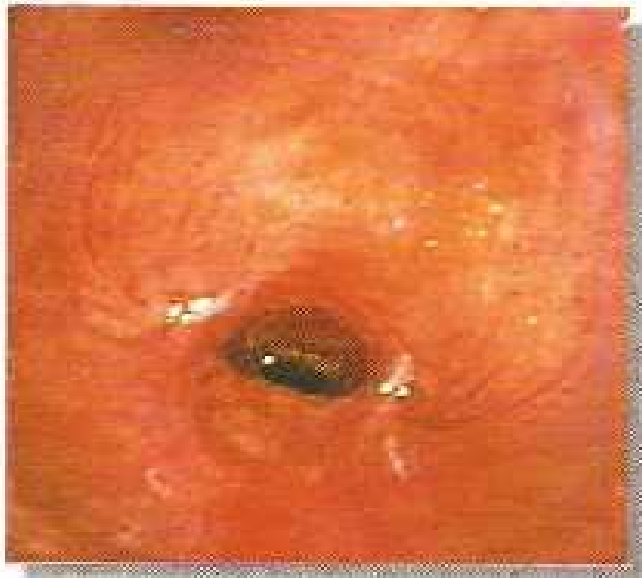

**Prolonged tracheostomy causing benign tracheoesophageal fistula.**

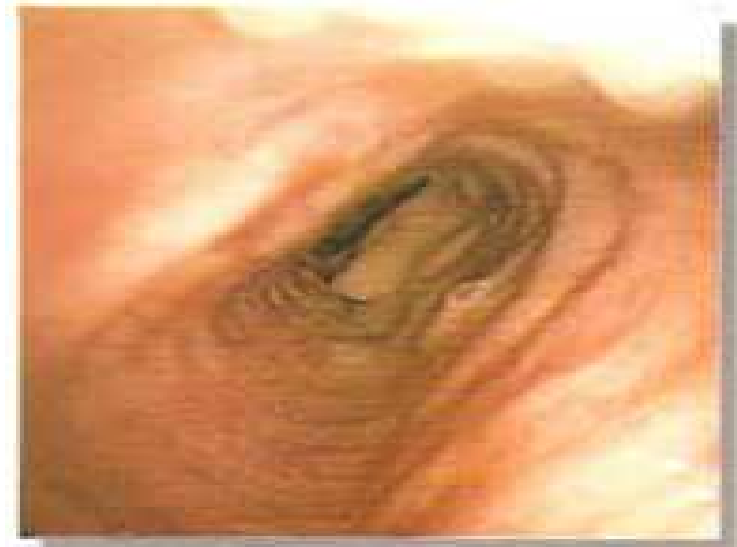

**Post tracheostomy circumferential web.**

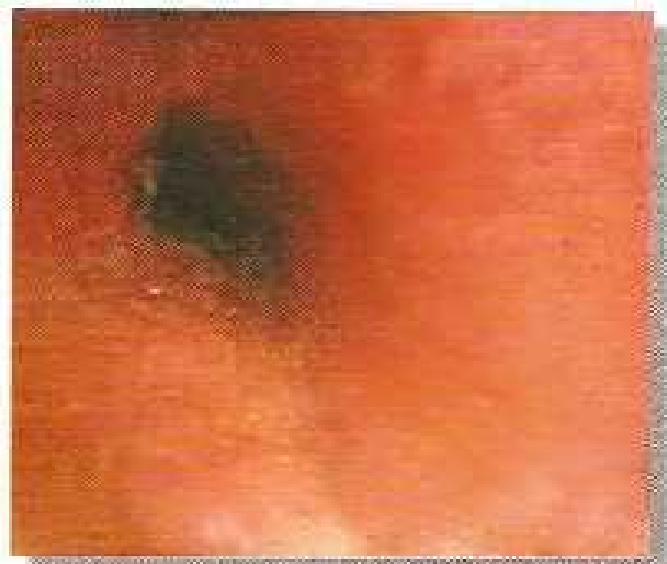AN INTRODUCTION TO BRONCHOSCOPY



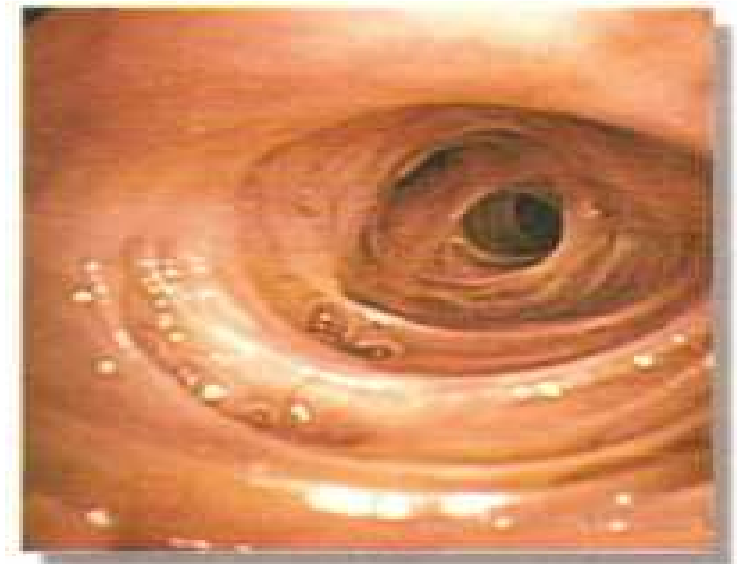**Post endotracheal intubation tracheal stenosis.**



**Trachenalacia**

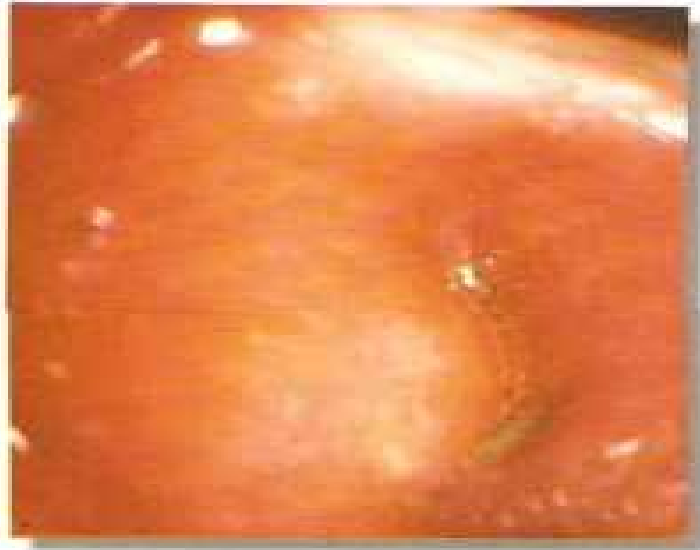

**Left lower lobe with tubercular stricture & granulation**

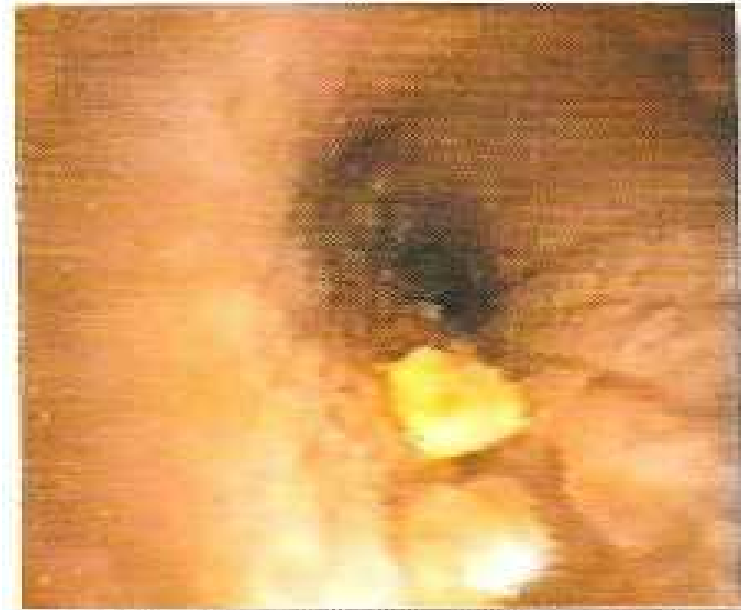

**Senile atrophic changes with tracheomalacia.**

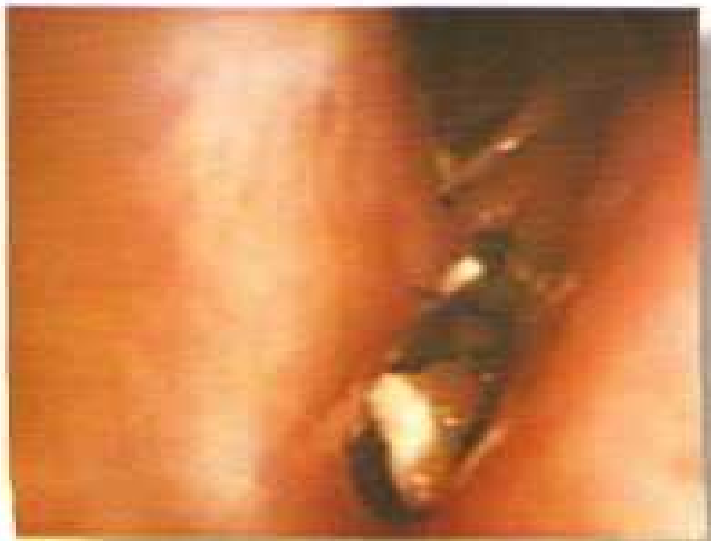AN INTRODUCTION TO BRONCHOSCOPY



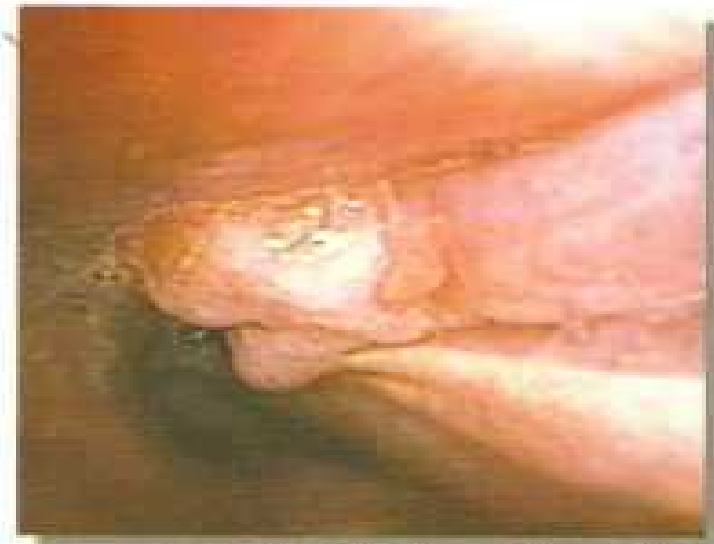**Post lobectomy bronchoscopic view of right lower lobe bronchus.**



**Bronchoscopic view of foreign bodies.**



**Right lobe post lobectomy fistula.**

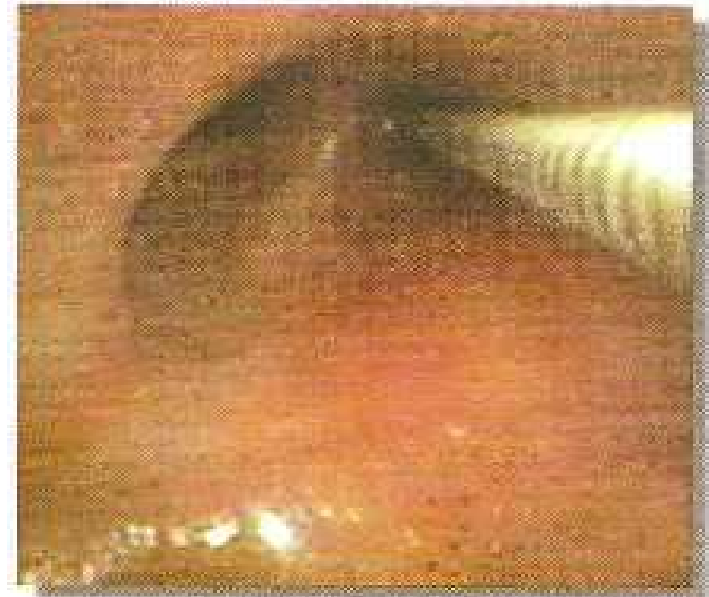

**Right major bronchus showing growth**

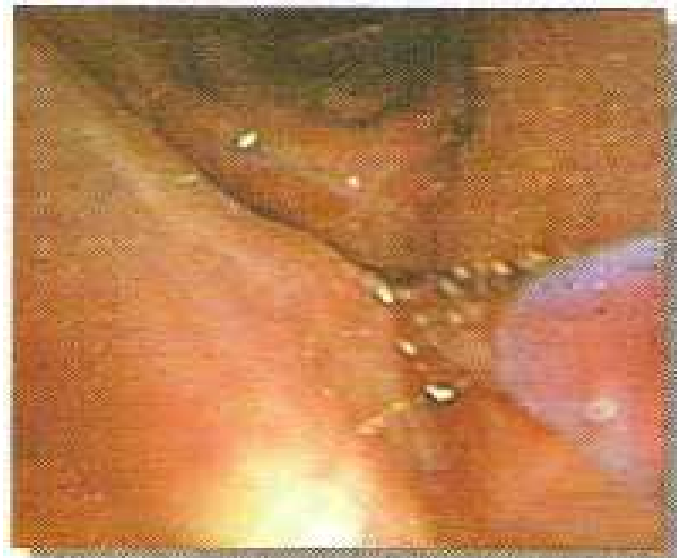AN INTRODUCTION TO BRONCHOSCOPY



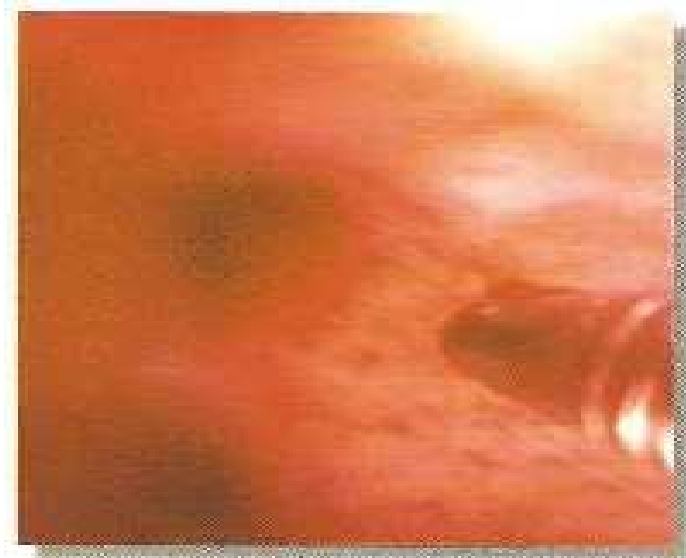**Forceps biopsy**



**Transbronchial biopsy**



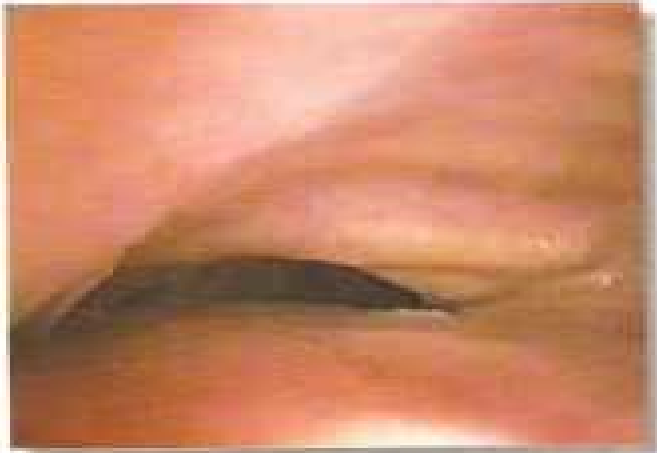**Brush biopsy**



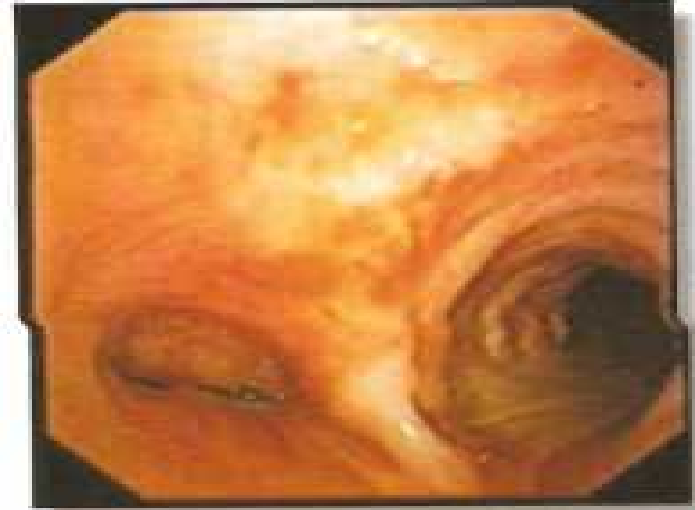**Bronchoscopic view of transbronchial needle aspiration**



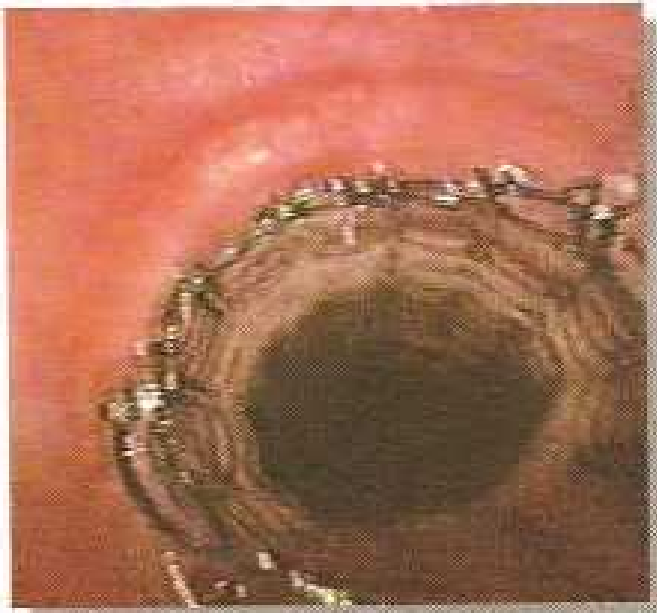AN INTRODUCTION TO BRONCHOSCOPY



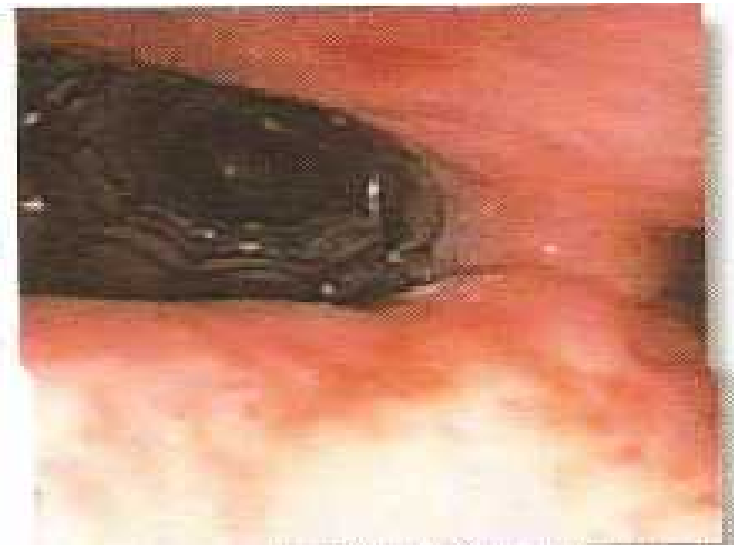**Extrinsic compression by carcinoma esophagus influencing tracheal lumen.**



**Left major bronchus compromised due to extrinsic pressure by enlarged metastatic lymph node.**

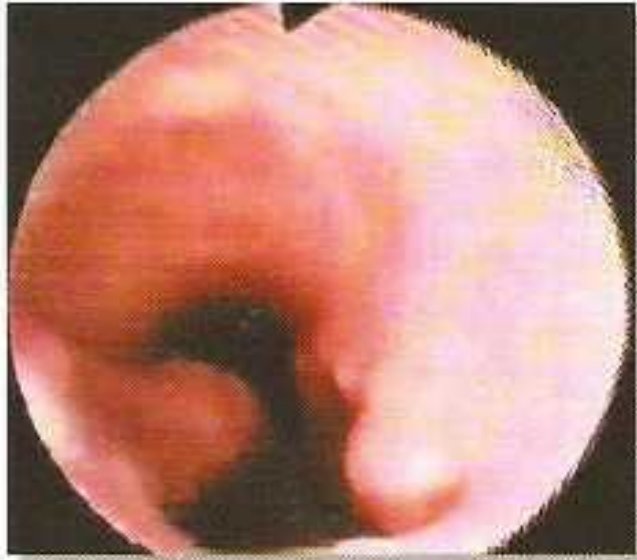

**Tracheal stent.**

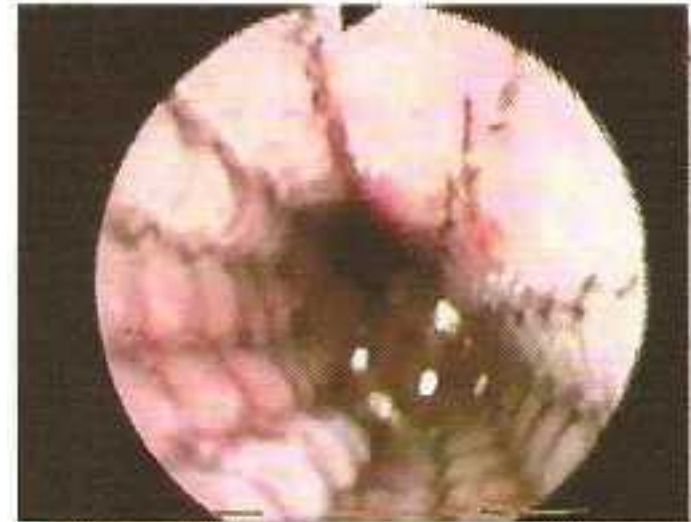

**Stent in left major bronchus.**

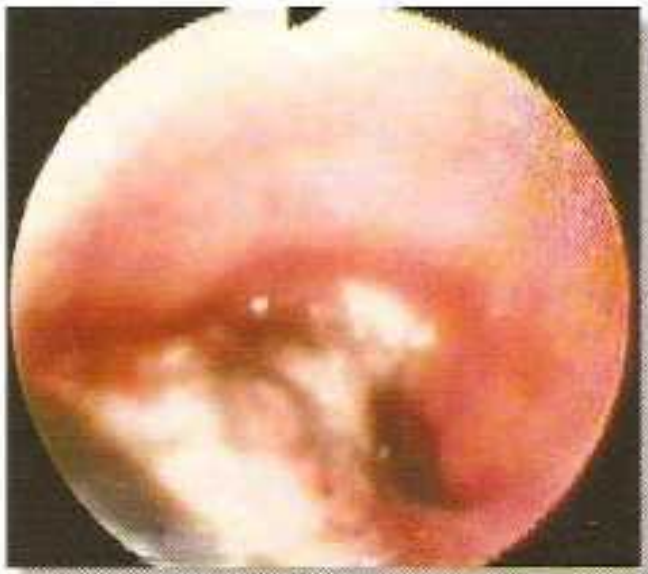AN INTRODUCTION TO BRONCHOSCOPY



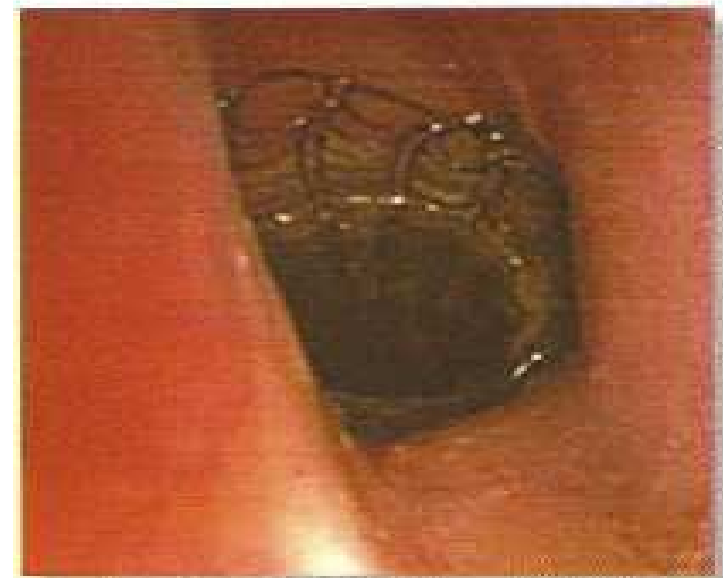**Gastrotracheal fistula**



**Stent in position, effectively covering airway fistula.**

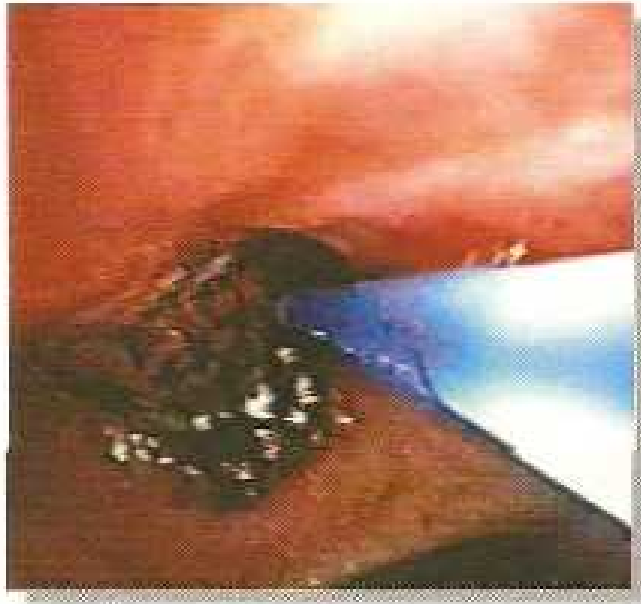

**A covered stent being placed.**

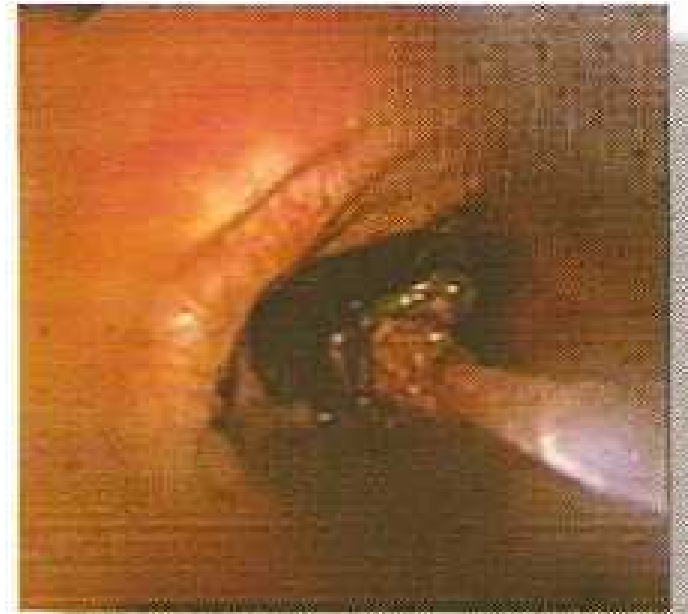


**Stent visible in subglottic area.**

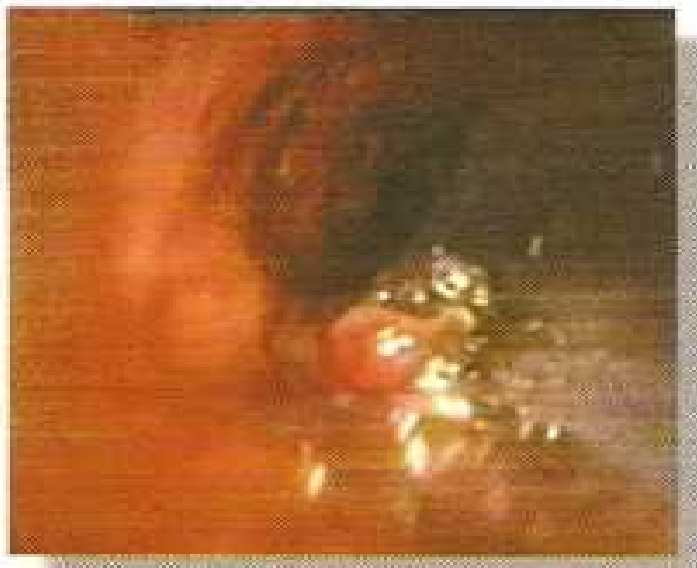AN INTRODUCTION TO BRONCHOSCOPY



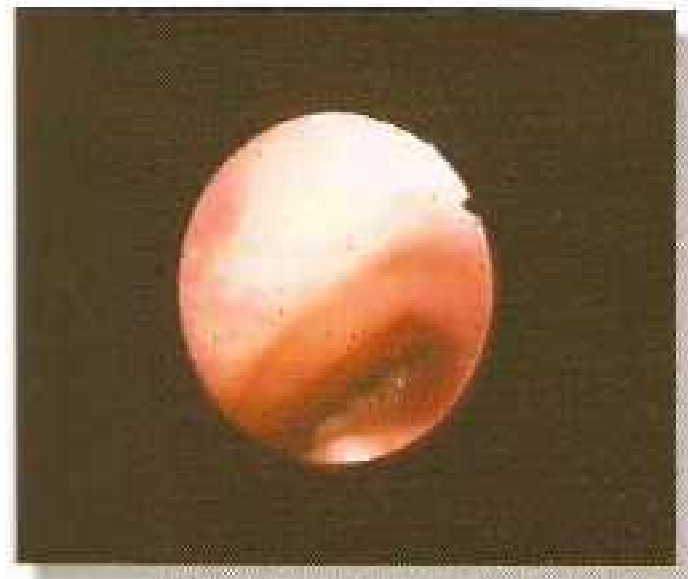**Brachytherapy**



**Charred tumour tissue following contact with laser probe.**

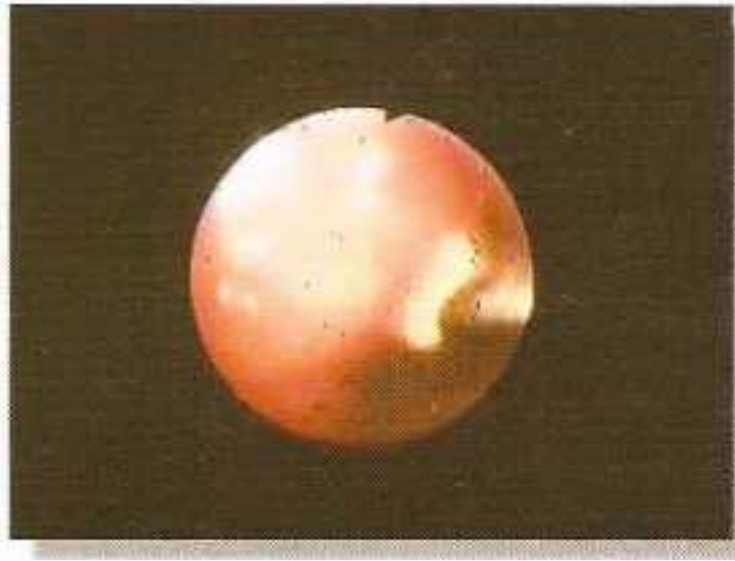

**Laser photocoagulation to debulk tumour mass.**

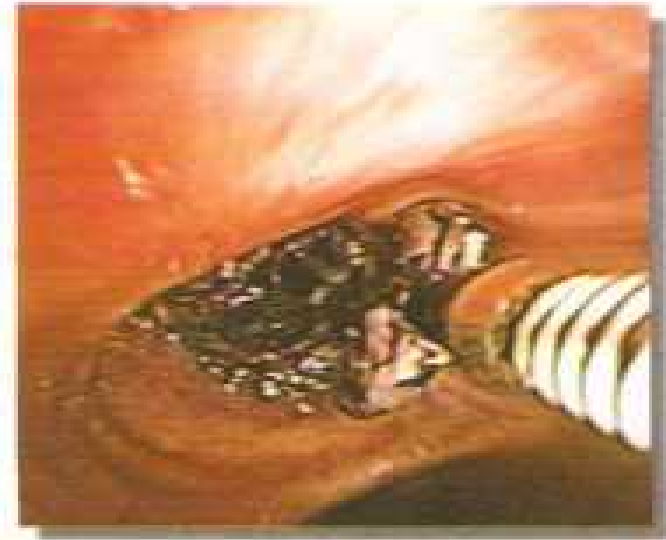

**Severely Compromised airway lumen by tracheal growth**

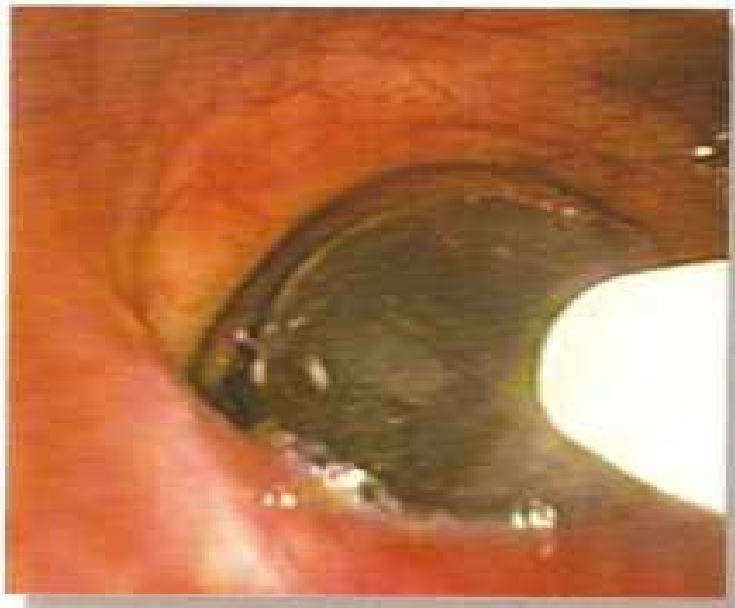
AN INTRODUCTION TO BRONCHOSCOPY



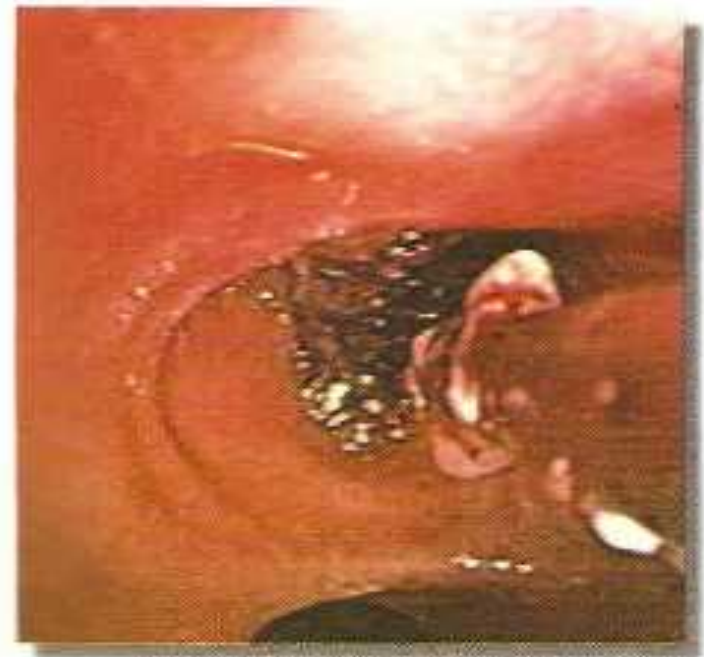**Tracheal growth photocoagulation with laser.**



**Biopsy forceps being used for deblinking of tumour mass.**



**Ballon Bronchoplasty**



**REFERENCE**

1. Sarkar SK, Newer innovations in bronchoscopy; Broncon 2005, 11-13th Feb: 2005 N. Delhi.
2. Summers RM; Navigational aids for real-time virtual bronchoscopy; AJR; 1997; 169: 1165-70.
3. Seeman MD; etal; Technical development hybrid rendering of the chest & virtual bronchoscopy Eurp Med Ref 2000; 30: 431-37.
4. Helmer RA, and Hunnigahake GW; Broncho alveolar lavage in the non compromised patient, Chest 1990;96: 1184-90.
5. Klech H, Pohl W; Technical recommendation and guidelines for Broncho Alveolar lavage! Report of the European Society of Pneumonology task Group on BAL Eur Respir J; 1989; 2: 561-65.
6. Antonelli M; etal; NIPPV via face mask during bronchoscopy with BAL in high risk hypodermic patients; Chest; 1996; 110: 724-28.
7. Xaubet A, Rodriguez - Roisin R, Bombi IA. Correlation of broncho alveolar lavage and clinical and functional findings in asbestosis; Am Rev Respir Dis; 1986; 133: 848-54.
8. Sestini P Rottoll L and Gotti G, BAL diagnosis of bronchalveolar carcinoma; Eur J Resp Dis; 1985; 66: 55-7.
9. Ajit Vigg; Role of BAL in diagnosis of peripheral lung cancer; Lung India 1991; 9: 61-2.
10. Reynolds HY; Interstitial lung diseases; Classification identibition and cosreation between clinical and histologic staging of interstitial lung diseases; Semin Resp Dis; 1984; 6: 1-9.
11. Haslam P, Furton CWG, Heard E. Bronchnoalveolar lavage in pulmonary fibrosis; Comparison of cells obtained with lung biopsy and clinical features; Thorax, 1980: 35; 9-18.
12. Wallalert B, Haston PY; Grosbosis JM; Subclinical pulmonary involvement in collagen vascular diseases assessed by bronchoalveolar lavage: Relationship between alveolitis and subsequents changes in lung functions. Am Rev Respir Dis, 1986; 133: 574-80.
13. Haslam PL Furton CWC and Luboszek A. Bronchoalveolar lavage fluid cell counts in cryptogenic fibrosing alveolitis and their relation to therapy; Thorax; 1986; 35: 328-39.
14. Bauwer W., Gorny MK., Baumann HR; T Lymhoocyte subsets and immuno globulin concentrations in bronchoalveolar lavage of patients with sarcoidosis and high and low intensity alveolitis; Am Rev Respir Dis.1985; 132: 1060-5.
15. Turner Warwick M, and Haslam P; The value of serial bronchoalveolar lavage in assessing the clinical progress of patients with crytogenic fibrosing alveolitis; Am Rev Respir dis, 1987: 135: 26-34.
16. Garg R etal; Pulmonary mucorymycosies mimicking as pulmonary TB- a case report, Lung India, 2008; 25: 129-31.
17. Hopkin JM, Turney JH, and Young JA. Rapid diagnosis of obscure pneumonia in immnosupressed renal patients by cytology of alveolar lavage fluid; Lancet 1983; ii: 2990301.
18. De blic j., MC Kelvie P and Le Bowrgeois M. Value of bronchoalveolar lavage in the management of severe acute pneumonia and interstitial pneumonitis in immunocompromised child; Thorax 1987; 42: 759-65.
19. Van Vyve T; etal; Safety of BAL & bronchial biopsies in patients with asthma of variable severity; Amer Rev RespDis, 1992, 146: 116-21.

## AN INTRODUCTION TO BRONCHOSCOPY

20. Krause A, etal; Cytokines derived from alveolar macrophage induce fever after bronchoscopy and BAL; Amer Respir Crit Care Med; 1997; 155; 1793-97.
21. Bhatia Rs; BAL-Indications and present status; Lung India; 1994; XII: 27-29.
22. Holgate ST; Lessons learnt from epidemic of asthma; Quet Journ Med; 2004; 97: 247-57.
23. Khan GQ, Bhatia RS; FOB; IN; RS Bhatia & GQ Kha ed; Pulmonary Med; Pee Pee Publishers; N Delhi; 2007;PP01-05.
24. Bilaceroglu S, Chhajed P; TBNA -a diagnostic tool in routine bronchoscopy; JAPI; 2005; 53: 797-802.
25. Bilaceroglu S, etal; TBNA -Asia -pacific experience, J. Bronchol ; 2004 ; 11 : 206- 14.
26. Colt HG ; etal; Bronchscopy in North America -The AAB Survey; J.Broncholo ; 2000; 7 : 8-25.
27. Harrow EM : etal; Letility of TBNA in staging of bronchogenic carcinoma; Am J Resp Crit Care Med 2000 ; 161 : 601-07.
28. Hermens FHW : etal ; Diagnostic yield of TBNA in patients with mediastinal lymph node enlargement: Respiration, 2003 : 70: 631-35
29. Trisolini R ; etal ; Value of flexible TBNA in diagnosis of stage I sarcoidosis; Chest: 2003; 124 : 426 -30.
30. Cetinkaya E ; etal : Diagnostic value of TBNA by Wan 22 gauge cytology needle in intrathoracic lymphadenopathy; Chest; 2004 ; 125 : 527 -31.
31. Bilaceroglu S; etal; TBNA in diagnosing intrathoracic tuberculous lymphadenitis; Chest; 2004; 126: 259 -67.
32. Chokhani R ; TBNA in the diagnosis of respiratory disease; Nepal Med CoII J; 2004 ; 6 : 24 -27.
33. Holty JE ; etal ; Accuracy of TBNA for mediastinal staging of NSCLC a meta analysis ; Thorax; 2005 ; 30.
34. Diacon AH; etal; Utility of ROSE of TBN aspirates; Respiration; 2005; 72: 182- 88.
35. Shankar S ; etal ; CT guided transthoracic fine needle aspiration versus transbronchial fluoroscopy –guided needle aspiration in pulmonary nodules; Acta Radil' 1998 ; 39 : 395 -99.
36. Kramer H, Groen HJ ; Current concepts in the mediastinal lymph node staging of NSCLC .Ann Surg; 2003 ; 238 : 180-88.
37. White CS; etal; TBNA: Guidance with CT fluoroscopy; Chest; 2000; 118: 1630- 38.
38. Herth F ;etal ; Conventional Vs endobronchial ultrasound guided TBNA -a randomised trial; Chest; 2004 ; 125 : 322 -25.
39. Herth FJ ; etal ; Transbronchial and transesophageal ultrasound guided aspiration of enlarged mediastinallymph nodes; Am J Resp Crit Care Med; 2005 ; 171 : 1164-67.
40. Rintoul R C ; etal ; Endobronchial and endoscopic ultrasound guided real time fine needle aspiration for mediastinal staging; Eur Resp J; 2005; 25 : 416-21.
41. Annema JT ; etal; Endoscopic ultrasound guided fine needle aspiration for diagnosis of sarcoidosis; Eur Resp.J.2005 ; 25 : 405-09
42. Ma GK ; etal; TBNA & PET in the diagnosis of lung cancer; J Bronch; 2004; 11 : 237-41.
43. Annema JT; etal; Towards a minimally invasive staging strategy in NSS LC -analysis of PET positive mediactinallesions by EUS-FNA; Lung Cancer; 2004;44 : 53-60.
44. Hsu LH;etal; TBNA guided integrated PET & CT; J:Bronchol ; 2005;12: 76 -80.
45. Becker HD; etal; Bronchoscopic biopsy of peripheral lung lesions under electromanetic guidance -a pilot study; J. Bronchol ; 2005 ; 12 : 9 -13.

## AN INTRODUCTION TO BRONCHOSCOPY

46. Schwarz y ; etal ; Electromagnetic navigation during flexible bronchoscopy; *Respiration*; 2003 ; 70 : 516 -22.
47. Schieppati E ; Le puncion mediastinal a traves del espolon traqueal; *Review of the Argentine Medical Association*; 1949; 663 : 497.
48. Wang KP; Terry PB; Transbronchial needle aspiration in diagnosis and staging of bronchogenic carcinoma; *Amer Rev Resp Dis*; 1983; 127 : 344-47.
49. Aggarwal AN; etal; Bronchoscopic lung biopsy for diagnosis of miliary TB; *Lung India*; 2005;22;116-18.
50. Sharma SK, Mohan A; Uncommon manifestations of sarcoidosis; *JAPI*; 2004;52:210-14.
51. Feller-Kopman D, Ernst A; Bronchoscopic needle aspiration and biopsy-requires routine use of real time imaging; *J.Bronchol*; 2001;8:309-13.
52. Turner JF; etal; Rigid bronchoscopy; *J Bronchol*; 2000; 7:171-76.
53. Herth F; Becker HD; Endobronchial ultrasound n in the airway and mediastinum; *Monaldi Arch- Chest Dis*; 2000; 55: 36-45.
54. Liewad F; etal; Comparison of virtual and fiberoptic bronchoscopy; *Thor Cardiovas Surg*; 1998; 46: 361-64.
55. Mc Adams Hp; etal; Virtual bronchoscopy for directing transbronchial needle aspiration of hilar and mediastinal lymph nodes: a pilot study; *AJR*; 1998; 170: 1361-64.
56. Prakash UBS; Bronchoscopy in critically ill patient; *Sem Res Med*; 1997; 18: 583-91.
57. Udaya BS Prakash; Advances in bronchoscopic procedures; *Chest*; 1999; 116: 1403-08.
58. Langendizk JA; etal; Massive haemoptysis after radiotherapy in inoperable NSCLC- is endobronchial brachytherapy really a risk factor? *Radiother Oncol* 1998; 48: 175-83.
59. Asmatulla H; etal; Endoscopic removal of tracheobronchial foreign bodies at a peripheral hospital; *Jour Post Grad Med Inst*; 2004; 18(3): 447-52.
60. Baharloo F; etal; Tracheobronchial foriegn bodies Presentation and management in children and adults *Chest*; 1999; 115(5): 1357-62.
61. Debljak a; etal; Bronchoscopic removal of foreign bodies in adults; *Eur Resp J*; 1999; 14(4): 792-95.
62. Meenu singh; etal; Role of flexible fibrotic bronchoscopy in the diagnosis of tracheobronchial foreign bodies in children: *Ind Paed*; 1999; 36: 386-89.
63. Hilmi OJ; etal; A randomized controlled trial of surgical task performance rigid bronchoscopy: Foreign body extraction with optical versus non- optical foreceps; *Clin Otolaryng All Scien*; 1999; 24: 499-501.
64. Vitor Cassol; eta!; Foreign body in children's airways; *Jor de Pneumol*; 2003; 29; May/June .
65. Rovin DJ; Rodgers BM; Paediatric foreign body aspiration: *Pediat Rev*; 2000; : 86-89.
66. Brown KL; etal; Near fatal grape aspiration with complicating acute lung injury successfully treated with extracorporeal membrane oxygenation; *Paed Crit Care Med*; 2003; 4(2): 243-45.
67. Burton EM; etal; Transbronchial foreign body aspiration in childhood; *South Air J*; 1996;89:195-98.
68. Dumon JF; etal; Seven year experience with Dumon prosthesis; *J Bronch*; 1996; 3: 6-10.
69. Raner ER; Beamis JF, Jr; Laser bronchoscopy; *Clin Chest Med*; 1995; 16: 415-26.
70. Shah H; etal ; Benign tumours of tracheo-bronchial tree; endoscopic characteristics and role of laser resection; *Chest*; 1995; 107: 1744-51.
71. Prakash UBS; Options in bronchoscopic therapy of airways neoplasm; *J Bronchol*; 1997; 4: 97-100.
72. Villanueva AG; etal; Endobronchial brachy therapy; *Clin Chest Med*; 1995; 16: 445-54.

## AN INTRODUCTION TO BRONCHOSCOPY

73. Sheski FD; Mathur PN; Cryotherapy, electro-cauty & brachy therapy; Clin Chest Med; 1999; 20: 123-38.
74. Cortese DA; etal; Photodynamic therapy for early stage squamous cell carcinoma of lung; Mayo Clinic Proc; 1997; 72: 595-602.
75. Bhatia Charya P, Mukerjee A; Role of FOB in diagnosis of pulmonary TB; in; RS Bhatia; ed; Tuberculosis, Pee Pee Publishers; N Delhi; 2007:PP-78-81.
76. Homasson JP; Bell NJ; Endotracheal electrocautery Semin Resp Clin Care Med; 1997; 18: 535-43.
77. Das gupta A; etal; Utility of tranbronchial needle aspiration in diagnosis of endobronchial lesions; Chest; 1999; 115: 1237-41.
78. Prakash UBS; Bronchoscopic resection of surgically resectable tracheobronchial neoplasms; J. Bronch 1996; 3: 85-87.
79. Haponik EF; etal Bronchoscopy training-current fellow's experiences and some concerns for the future; Chest; 2000;118:625-30.
80. Cost HG; etal; Virtual reality bronchoscopy simulation –a revolution in procedural training; Chest; 2001;120:1333-39.
81. Colt HG; etal ; Bronchoscopy in North American Association for Bronchoscopy; Journ Bronchol 2000;7:08-25.
82. Miller JI Jr; Rigid bronchoscopy; Chest Surg Clin North Amer; 1996; 6:161-67.
83. Cooper JD; etal; Use of silicone stents in the management of airway problems; Amer Thorac Surg;1998;47:371-78.
84. Hetzel Mr, Smith SG; Endoscopic palliation of tracheobronchial malignancies; Thorax; 1991; 46:325-33.
85. Grover UK; Frequency of ischeamic changes and arrythmias during upper airway endoscopy. J Anaesth Clin Pharmacol; 2009;25:157-60.
86. Wedzicha JA, Pearson MC; Management of massive haemophtsis; Respir Med; 1990; 84:09-12.
87. Honeybourne D; etal; British Thoracic Society guidelines on diagnostic flexible bronchoscopy; Thorax; 2001; 156:i1-i2.
88. Prakash UBS; etal; Bronchoscopy in North America; the ACCP survey; Chest ; 1991;100:1668-75.
89. Lechtzin N. Rubin HR, White PJr, etal; Patient satisfaction with bronchoscopy; Amer J Resp Crit Care Med; 2002; 166:1326-31.
90. Colt H, Powers A, Shanks TG; Effect of music on state anxiety scores in patients undergoing fiberoptic bronchoscopy; Chest; 1999; 116:819-24.
91. Atul C Mehta; Don't loose the forest for the trees; Satisfaction and success in bronchoscopy, Amer J Resp Crit Cared Med; 2002;116:306-07.
92. Burton EM; etal; Transbroncial foreign body aspiration in children, South Afr. J; 1996; 89:195-98.
93. Wiseman NE; The diagnosis of foreign body aspiration in childhood; J Paediat Surg; 1984;19:513-35.
94. Lima JAB; etal; Aspiracao de corpo estranho na; J Pneumol; 2000;26:20-24.
95. Hoeve LJ; etal; Foreign body aspiration in children; the diagnostic value of signs, symptoms and pre-operative examination; Clin Otolaryngol; 1993;18:55-57.
96. Perez CR; Wood RE; Update on Peadiatric flexible bronchoscopy; Paediat Clin North Amer; 1994;41:385-400.
97. Limper AH; Parkash UBS; Transbronchial foreign bodies in adults; Amer Intern Med; 1990;112:604-09.
98. Sen MK; Suri JC; Therapeutic bronchoscopy; Ind J Chest Dis Allied Sciences; 2000;42:167-79.
99. Mu L; etal; Inhalation of foreign bodies in Chinese children; A review of 400 cases; Laryngoscope; 1991;101:657-60.



## AN INTRODUCTION TO BRONCHOSCOPY

100. Ahmed AA; Bronchoscopic extraction of aspirated foreign bodies in children in Harare Central Hospital; *Cent Afr J Med*; 1994;40:183-86.
101. Bittercourt PFS, Camragos PAM, Aspiracao de corps estranhos; *J Peaditr*; 2002;77:9-18
102. Mugles LA etal; Paediatric tracheobronchial foreign bodies; Historical review from the Johns Hopkins Hospital; *Ann Otol Rhinol Laryngol*; 1996;105:556-61
103. Wolach B etal; Aspirated foreign bodies in the respiratory tract of children; Eleven years experience with 127 patients; *Int J Paed Otolaryngol*; 1994;30:1-10
104. Lan RS; Non asphyxiating trancheobronchial foreign bodies in adults; *Eur Resp J*; 1994;7:510-14.
105. Martinol A, etal; Indications for flexible versus rigid bronchoscopy in children with suspected foreign body aspiration; *Amer J Resp*; *Amer J Resp J Crit Care Med*; 1997;155:1676-79.
106. Tietjen PA etal; Aspiration emergencies; *Clin Chest Med*; 1994;15:117-35.
107. National Safety Council Deaths due to unintentional injuries; 1999; <http://www.nsc.org>.
108. Killian G; Meeting of the Society of Physicians Freiburg; Dec 17; 1897; *Munchen Med Wsher*; 1898;45:378.
109. Ikeda S; etal; Flexible Bronchoscope; *Keio J Med* 1968;17:1-16.
110. Bhatia RS; Sibia SS; Therapeutic use of FOB; *Lung India*; 1994;12:138-39.
111. Schellhase DE; Paediatric Flexible bronchoscopy: *Curr Opin Paediat*; 2002;14:327-33
112. Swanson KL; etal; Flexible Bronchoscopic management of airway foreign bodies in children *Chest*; 2002;121:1695-1700.
113. Bolliger CT; Airway stents; *Semin Resp Crit Care Med* 1997;18:563-70.
114. Lee P Kupeli E, Mehta AC. Therapeutic bronchoscopy in lung cancer. Laser therapy, electrocautery brachytherapy, stents, and photo dynamic therapy; *Clin Chest Med* 2002; 23: 241-56.
115. Helters. RA. Sanderson DR. Rigid bronchoscopy. The forgotten art. *Clin Chest Med* 1995, 16:393-399.
116. Duhamel DR. Harreli JH: Laser bronchoscopy. *Chest Surg Clin N Am* 2001;11:769-89.
117. Mehta A, Lee FY, De Boer G. Flexible bronchoscopy and the use of Lasers. In: Wang K P Metha A, eds. Flexible bronchoscopy. Massachusetts: Blackwell Science, 1995: 247-74.
118. Beamls JF, Jr., Vergos K, Rebelz EE, et al. Endoscopic laser therapy for obstructing tracheobronchial lesions. *Ann Otol Rhinol Laryngol* 1991; 100:413-419.
119. Stanopoulos IT, Beamis JF, Jr., Martinez FJ, et al. Laser bronchoscopy in respiratory failure from malignant airway obstruction; *Crit Care Med* 1993: 21:386-391.
120. Garden JM, O'Banion MK, Snelnitz IS, et al. Papilloma virus in the vapours of carbon dioxide laser-treated verrucea, *JAMA* 1988;259:1199-202.
121. Baggish MS, Poiez BJ, Joret D, et al. Presence of human immunodeficiency virus DNA in laser smoke *Laser Surg Med* 1991;11: 197-203.
122. Bhatia RS, Sibia SS, Management of spontaneous pneumothorax, IN: S Venkataraman ed, *Med Update API*, 2004, 14:221-26.
123. Sutedja G, van Boxem TJ, Schramel FM Endobronchial electrocautery is an excellent alternative for Nd; YAG laser to treat airways tumours; *J Bronchology* 1997;4:101-5.
124. Sutedja G, van Kralingen K, Schramel FM, et al. Fiberoptic bronchoscopic electrosurgery under local anaesthesia for rapid palliation in patients with central

- airways malignancies: a preliminary report. *Thorax* 1994;49:12 43-1246.
125. Krawtz S, Mehta AC, Wiedemann HP, et al. Nd: YAG laser induced endobronchial burn: Management and long term follow-up. *Chest* 1989;95:916-8.
  126. Miro AM, Ivaram U, Fuch PJ. Noncardiogenic pulmonary oedema following laser therapy of a tracheal neoplasm. *Chest* 1989;96: 1430-1.
  127. Fairfax WR, Rollins RJ. Pulmonary hyperinflation following Nd:YAG laser resection of an obstruction main stem tumor *Chest* 1986;93:782-85.
  128. Peachey T, Eason J, Moxham D, et al. Systemic air embolism during laser bronchoscopy. *Anaesthesia* 1988;43:872-5.
  129. Dumon JF, Shapsay SM, Bourcereau J, et al. Principles for safety in application of Neodymium- YAG laser in bronchology. *Chest* 1984;86: 163-8.
  130. Rossi et al, CT guided radiofrequency ablation a potential complementary therapy for patients with unresectable primary lung cancer; *AJR*:2004; 183 (4).
  131. Coulter TD, Mehta AC. The heat is on impact of endobronchial electro-surgery on the need for Nd: YAG laser photo resection. *Chest* 2000; 118:516-21
  132. Morice RC, Ece T, Ece F, et al Endobronchial argon plasma coagulation for treatment of hemoptysis and neoplastic airway obstruction. *Chest* 2001; 119:781-787.
  133. Colt HG; Bronchoscopic resection of wallstent associated granulation tissue using argon plasma coagulation. *J Bronchology* 1995;5:209-212.
  134. Sheshi FD; Mathur PN; Cryotherapy, electro cautery, and brachytherapy; *Clin Chest Med*; 1999;20:123-38
  135. Mag S; et al; Brachytherapy for carcinoma lung; *oncology*; 2001;15:371-81,
  136. Miller JI, Jr., Phillips. TW. Neodymium :YAG laser and brachytherapy in the management of inoperable bronchogenic carcinoma. *Ann Thoracic Surg* 1990;50:190-95; discussion 195-95.
  137. Kennedy AS, Sonnett JR, Orens JB, et al. High dose rate brachytherapy to prevent recurrent benign hyperplasia in lung transplant bronchi: theoretical and clinical considerations; *J Heart Lung Transplant* 2000;19:155-59.
  138. Hennequin C. Tredaniel J, Cheveret S, et al. Predictive factors for late toxicity after endobronchial brachytherapy a multivariate analysis. *Int J Radiat Oncol Biol Phys* 1998; 42:21-27.
  139. Rubinsky B, Ikeda M. A Cryomicroscope using directional solidification for the controlled freezing of biological tissue. *Cryobiology* 1985;22:55-59.
  140. Guidelines from American College of Chest Physicians; *Chest*; 2003;123:1693-1717.
  141. Mathur PN, Wolf KM, Busk MF, et al. Fiberoptic bronchoscopy cryotherapy in the management of tracheobronchial obstruction. *Chest* 1996;110:718-23.
  142. Deygas N, Froudarakis M, Ozenne G, et al. Cryotherapy in early superficial bronchogenic carcinoma; *Chest* 2001;120:26-31.
  143. Kato H; et al; Phase II clinical study of photo dynamic therapy using mono-L-aspartic chlorine and diode laser for early superficial squamous cell carcinoma of lung : *Lung Cancer* ;2003;42:103-11.
  144. Konaka C, Okunaka T, Furukawa K, et al. Laser photo dynamic therapy for central type lung cancer. *Nihon Kyobu Shikkan Gakkai Zasshi* 1996;34 suppl. 107-110.
  145. Kusunoki; Y; et al; Early detection of lung cancer with laser induced fluorescence endoscopy & spectrofluorometry; *Chest* 2000;118:1776-82.
  146. Van Boxem A J, Westerga J, Venmans BJ, Postmus PE, Sutedja G. Photodynamic therapy, Nd: YAG laser and electrocautery for treating early stage intraluminal cancer- which to choose? *Lung Cancer* 2001;31:31-6

## AN INTRODUCTION TO BRONCHOSCOPY

147. Vonk-Noordegraaf A, Postmus PE, Suttedja TG. Bronchoscopic treatment of patients with intraluminal micro invasive radiologically occult lung cancer not eligible for surgical resection-a follow up study. *Lung Cancer* 2003;39:49-53.
148. Cortese DA, Kinsey JH. Hematoporphyrin derivative phototherapy in the treatment of bronchogenic carcinoma. *Chest* 1984;86: 8-13.
149. Shaffer JF, Allen JN. The use of expandable metal stents to facilitate extubation in patients with large airway obstruction. *Chest* 1998; 114: 1378-382.
150. Dumon JF, Cavalieres, Diaz, Jimenez JP, et al. Seven years experience with the Dumon prosthesis. *J Bronchology* 1996;31:6-10.
151. Miyazawa T, Yamakido M, Ikeda S, et al. Implantation of ultraflex nitinol stents in malignant tracheobronchial stenosis. *Chest* 2000; 118:959-65.
152. Chhajed PN, Malouf MA, Tamm M, et al. Ultraflex stents for the management of airway complications in lung transplant recipients; *Respirology* 2003; 8:59-64.
153. Mehta AC, Dasgupta A. Airway stents. *Clin Chest Med* 1999;20:139-151.
154. Rafanan AL, Mehta AC. Stenting of the tracheobronchial tree. *Radiol Clin North Am* 2000;38:395-408.
155. Chhajed PN, Malouf MA, Tamm M, et al. Interventional bronchoscopy for the management of airway complications following lung transplantation. *Chest* 2001; 120: 1894-99
156. Chhajed PN, Malouf M, Chhajed TP, et al. Utility of covered metallic airway stents in the management of tracheo-oesophageal fistulae. *Am J Respir Crit Care Med* 2001;167: A535.
157. Goyal MK; Diwan A, Arora SS, Nangia V; et al; Airway stenting: An Indian experience; NCCP award session, NAPCON 2004, (Abst): P 100-101
158. Chhajed PN, Malouf MA, Glanville AR. Bronchoscopic dilatation in the management benign (nontransplant) tracheobronchial stenosis. *Intern Med J* 2001; 31: 512-16.
159. Sheski FD, Mathur PN. Long term results of fiberoptic bronchoscopic balloon dilatation in the management of benign tracheobronchial stenosis. *Chest* 1998; 114:796-800.
160. David O, Boasley MB, Minardi AJ Jr, Malek F, Kovit KL. Management of endobronchial hamartoma. *J La State Med Soc* 2003; 155: 110-2.
161. Chhajed PN, Bretsche M, Tamm M. Balloon dilatation using flexible bronchoscopy for the management of benign and malignant airway stenoses. *Chest* 2004; 125:354-55.
162. Kiriyama M, Fujii Y, Yamakawa Y, et al. Endobronchial neodymium Yttriumaluminium garnet laser for noninvasive closure of small proximal bronchial fistula after lung resection. *Am Thorac Surg* 2002;2.
163. Madden BP, Datta S, Mc Anulty G. Tracheal granulation tissue after percutaneous tracheostomy treated with Nd YAG laser three cases. *J Laryngol Otol* 2001; 115:743-4
164. Madden BP, Lee M, Paruchuru P. Successful treatment of endobronchial amyloidosis using Nd: YAG laser therapy as an alternative to lobectomy. *Monaldi Arch Chest Dis* 2001;56:27-9
165. Gallivan GJ. Bilateral vocal fold posterior glottic/subglottic stenotic web resected with contact tip Nd-YAG laser; *J Voice* 2002;16:415-21.
166. Mehta AC, Lee FY, Cordasco EM, et al. Concentric tracheal and subglottic stenosis management using the Nd-YAG laser for mucosal sparing followed by gentle dilatation; *Chest* 1993;104: 673-677.
167. Noppen M; Schiesser M, Meysman M, et al. Bronchoscopic balloon dilatation in the combined management of postintubation stenosis of the trachea in adults. *Chest* 1997; 112:1136-1140.

## AN INTRODUCTION TO BRONCHOSCOPY

168. Haponik EF, Chin R. Hemoptysis: clinician's perspectives. *Chest* 1990;97:469-475.
169. Abhyankar NY; Bhambure NM, Gandhi YP; et al; Management of haemoptysis by bronchoscopic infusion of Batrosobin, *Lung India*; 1990;4:195-98.
170. Dweik RA, Stoller JK Role of bronchoscopy in massive hemoptysis. *Clin Chest Med* 1999;20:89-105.
171. Saw EC, Gottlieb LS, Yokoyama T, et al. Flexible fiberoptic bronchoscopy and endobronchial tamponade in the management of massive hemoptysis. *Chest* 1976;70:589-91.
172. Swersky RB, Chang JB, Wisoff BG, et al. Endobronchial balloon tamponade of hemoptysis in patients with cystic fibrosis. *Ann Thorac Surg* 1979; 27:262-64.
173. Kato R, Sawafuji M, Kawamura M, et al. Massive hemoptysis successfully treated by modified bronchoscopic balloon tamponade technique. *Chest* 1996;109:842-43.
174. Ovassapian A, Randel GI. The role of the fiberscope in the critically ill patient. *Crit Care Clin* 1995, 11:29-51.
175. Sivarajan M, Stoller E, Kil HK, et al Jet ventilation using fiberoptic bronchoscopes; *Anesth Analg* 1995; 80:384-87.
176. Lang DM, Simon RA, Mathison DA, et al. Safety and possible efficacy of fiberoptic bronchoscopy with lavage in the management of refractory asthma with mucous impaction. *Ann Allergy* 199;67:324-30.
177. Henke CA, Hertz M, Gustafson P. Combined bronchoscopy and mucolytic therapy for patients with severe refractory status asthmaticus on mechanical ventilation a case report and review of the literature. *Crit Care Med* 1994;22:1880-83.
178. Joliet P, Chevrollet IG Bronchoscopy in the intensive care unit. *Intensive Care Med* 1992;18:160-69.
179. Thomas Change Yao Pharo, Zing-Huang Tsa, Ray- Shee I AN; et al; Treatment for collapsed lung in critically ill patients: Selective intra bronchial air insufflation using FOB, *Chest*; 1990;97: 435-38.
180. Steven RP, Lillington GA, Parsons GH. Fiberoptic bronchoscopy in the intensive care unit. *Heart Lung* 1981; 10:1037-1045.
181. Ernst A; et al; Percutaneous tracheostomy ; *J: Bronchol*; 1998;05;247-50.
182. Noppen M. Percutaneous dilatational tracheostomy. In; Bolliger CT, Mathur P, ed; *Interventional Bronchoscopy* Basel Karger. 2000:215-225.
183. Hazard P Jones C Benlton; Comparative clinical trial of standard operative tracheostomy with per cutaneous tracheostomy . *Crit Care Med* 1991;19:1018-24.
184. Frecman BD; et al; A meta analysis of prospective trials comparing percutaneous and surgical tracheostomy in critically ill patients *Chest*. 2000;118;1412-18.
185. Fischler M. Kuhn M, Cantieni R, et al Late outcome of percutaneous dilatational tracheostomy in intensive care patients; *Inten Care Med*: 1995;21:475-81.
186. Rafanan AL, Mehta AC. Adult airway foreign body removal. What's new? *Scientific Publ. NAPCON*; 2004; P 47-53.
187. Menivale F; et al; Therapeutic management of broncholithiasis; *Ann Thoracic Surg*; 2005;79:1774-76.
188. Jairam S, Santoshan R, Sasank HRK, Santopham R, Foreign body in the lung, *NAPCON 2004*, Adst:P84.
189. Danel C, Israel-Biet-D, Costabel U, et al. Therapeutic applications of bronchoalveolar lavage. *Eur Respir* 1992;5: 1173-1175
190. Roger R M, Szidon J P, Shelburne J, et al . Haemodynamic response of the pulmonary circulation to bronchopulmonary lavage in man. *N Engl J Med* 1972; 286:1230-33.
191. Nagasaka Y, Takahashi M, Ueshima H, et al. Bronchoalveolar lavage with trypsin in pulmonary alveolar proteinosis. *Thorax* 1996;51:769-770.

## AN INTRODUCTION TO BRONCHOSCOPY

192. Sirivella S, Ford WR, et al. Foregut cysts of the mediastinum; Results of 20 surgically treated cases; J Thoracic Cardiovas Surg; 1985;90:776-82.
  193. Sidman JD, Wheeler WB, Kabalka AK, Soumekh B, Brown CA, Wright GB. Management of acute pulmonary haemorrhage in children; Laryngoscope 2001;111:33-5.
  194. Wiedemann HP, Taidy. Adult Respiratory Distress Syndrome (ARDS): Current management, future directions. Cleve Clin J Med 1997;64:365-72.
  195. Sippel JM, Mark S, Chesnutt MS, Bronchoscopic therapy for broncho pleural fistulas. J Bronchology 1998;5:61-69.
  196. Chhajed PN, Lee Pyng, Tamm M; Advances in bronchoscopy-New and upcoming bronchopic methods at the dawn of the twenty first century; JAPI;2004;52:970-74.
  197. Nicolai T. Paediatric bronchoscopy: Paediats Pulmonol; 2001;31: 150-64
  198. Bush Andrew: Paediatric bronchoscopy in the NICO & PICU; IN; Bronco Con 2005; 11-13th Feb; New Delhi
  199. Midulla F; etal; FOB of pediatric airway; Eurp Resp J; 2003; 22: 698-708.
  200. Sekaran DV; FOB & BAL in lung diseases; Pediatrics Today; 2003; 6;279-87
  201. Bala chandran A; etal; Bronchoscopy talks to you: Ind J Pediat;2004;71:739-42.
  202. Sheski FB, Mathur PN; EBUS ;Chest; 2008; 133: 264-70.
  203. Yoslikacoa M; etal: Sheath for peripheral pulmonary lesions without x-ray fluoroscopy diagnostic value of EBSU with a guide: Chast; 2007;131:1788-93
  204. Silvestri GA; elal; Noninvasive staging of non small cell lung cancer: ACCP evidenced based clinical practice guidelines; Chest; 2007;132:178 S-201S.
  205. Herth FJ: etal; EBUS with trans bronchial needle aspiration for restaging mediastinum in lung cancer; J Chin Oncol; 2008; 26; 3346-50.
  206. Garwood S; etal; EBUS for diagnosis of pulmonary sarcoidosis; Chest ; 2007: 132:1298-304.
  207. Peter WA: etal: Combined EBUS real time TBNA & conuentional TBNA are most cost effective means of lymph node staging; J. Bronchol;2008;15:17-20.
- 
-

## AN INTRODUCTION TO BRONCHOSCOPY



**AN INTRODUCTION TO BRONCHOSCOPY**

**AN INTRODUCTION TO BRONCHOSCOPY**